

Physiological periostitis in a 2.5-month-old baby

Oya Halıcıoğlu¹, Sezin Aşık-Akman¹, Işın Yaprak¹, Görkem Astarıcıoğlu¹, Tuna İmamoğlu², Ali Reisoğlu³

Departments of ¹Pediatrics, ²Radiology, and ³Orthopedics and Traumatology, The Ministry of Health Tepecik Training and Research Hospital, İzmir, Turkey

SUMMARY: Halıcıoğlu O, Aşık-Akman S, Yaprak I, Astarıcıoğlu G, İmamoğlu T, Reisoğlu A. Physiological periostitis in a 2.5-month-old baby. Turk J Pediatr 2009; 51: 305-307.

Periosteal reaction has different etiologies in early infancy. Physiological periostitis is a well- documented X-ray finding seen in both preterm and term babies aged between 1-6 months and can easily be misdiagnosed as child abuse or pathological periostitis. Here, we present a 2.5-month-old infant admitted with a history of fever, swollen right upper arm after vaccination and X-rays findings revealing periosteal reactions on both sides of the humeri, radii, tibiae and femora. Initial diagnosis was child abuse or congenital syphilis. Due to the normal physical findings and normal serological-biochemical data, physiological periostitis was diagnosed. Physiological periostitis should also be considered in patients with periosteal reactions of the long bones in infants aged between 1-6 months.

Key words: periostitis, physiological, infant.

Physiological periostitis (or periosteal new bone formation) is a known radiological finding in both preterm and term infants aged between 1 and 6 months, and the exact etiology of this condition is unknown. It is commonly seen in long bones and is invariably symmetrical in distribution, although occasionally more prominent on one side than the other. The femora, humeri and tibiae are affected almost equally, but may be limited to one pair of bones initially. It is always on the diaphysis and usually asymptomatic¹. In the differential diagnosis of periosteal reaction, it can be confused with other causes of pathological periostitis such as child abuse, syphilis, osteomyelitis, trauma, bone tumor and tumor-like lesion; thus, radiological analysis must be done carefully^{2,3}. In the literature, there are few case reports about physiological periostitis. It is a condition that should be known well in order to avoid more aggressive laboratory testings of infants. We therefore report this case to call the attention of physicians to this self-limited condition.

Case Report

A 2.5-month-old male baby was referred to the emergency service of our hospital with the complaints of swollen left upper arm irritability

two days after vaccination. X-ray studies found periosteal reactions on both sides of the humeri, radii, tibiae and femora. History revealed that he had had fever lasting for a day following vaccination, and was born to a gravid 1 partum 1 mother at 35 weeks' gestation by cesarean section, weighing 1600 g. He was small for gestational age. He was breast-fed and sucking reflex was not poor. Physical examination was within normal limits, with weight: 4200 g (25-50 p), length: 52 cm (10 p), head circumference: 36 cm (75-90 p), heart rate: 130/ minute, respiratory rate: 32/ minute, and anterior fontanel: 2x2 cm. Arousal and activity were normal. The right upper arm where the vaccine was injected was swollen. Other findings and neuromotor milestones were normal. Laboratory tests revealed white blood cells (WBC): 5,600/mm³, red blood cells (RBC): 2,800,000/mm³, hemoglobin (Hb): 9.5 g/ dl, hematocrit (Htc): 25.2%, mean corpuscular volume (MCV): 84.2 fl, and platelets (PLT): 324,000/ mm³; peripheral blood smear formulation was 22% neutrophils, 74% lymphocytes, 4% monocytes. Biochemical analysis showed calcium (Ca): 9.4 mg/dl, phosphorus (P): 4.2 mg/dl, alkaline phosphatase: 1741 U/ L, and creatine kinase: 53 U/L; liver and renal function tests and other ions were all within normal limits.

X-ray bone survey for differential diagnosis revealed periosteal reactions of the entire bone axis in all long bones of the extremities (humeri, radii, ulnae, tibiae, femora) (Figs. 1, 2). There was no trauma history and screening for

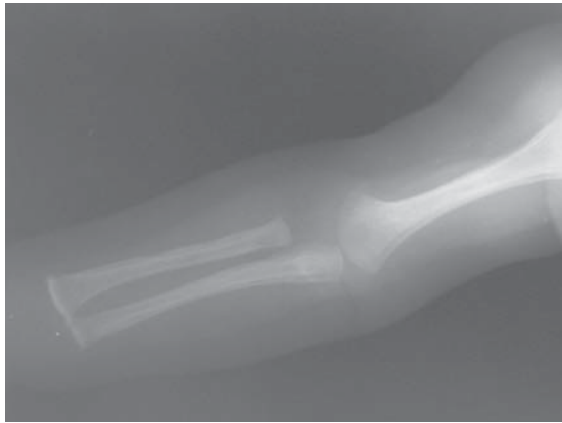


Fig. 1.

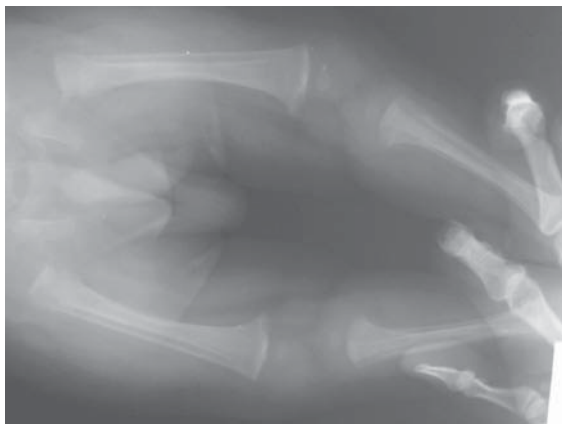


Fig. 2.

Fig. 1, 2. Periosteal reactions of the entire bone axis in the long bones of all extremities.

infection was normal (erythrocyte sedimentation rate: 18 mm/hour, C-reactive protein: 0.8 mg/dl; urinary and blood cultures were negative). Rapid plasma reagin (RPR) and *T. pallidum* hemagglutination test (TPHA) for syphilis were within normal limits in both mother and the patient. There were no signs and symptoms like fever, malaise or limitation of movements. The findings of the left upper arm had recovered in three days and it was diagnosed as vaccination reaction. Radiological findings at the age of six months were normal.

Discussion

Physiological periostitis is a well-documented X-ray finding in preterm and term infants aged between 1-6 months. It is commonly seen in long bones and is invariably symmetrical in distribution, although occasionally more prominent on one side than the other. It is always on the diaphysis and there is no consistency as to the site of involvement except in the tibia, where the new bone is invariably on the medial aspect. It is always asymptomatic and the etiology is unknown¹.

The periosteal membrane surrounds all cortical bone surfaces except the joint surface. The inner layer of the periosteal membrane is more active in infants than in adults. Physiological alterations in this layer on periosteal reactions due to irregularities of cortical bones can be misdiagnosed as pathological periostitis^{1,2}. Hypervitaminosis A, prostaglandin administration, infantile cortical hyperostosis (Caffey disease), osteomyelitis, trauma, leukemia, malignancies that can metastasize to bones, rickets, syphilis and rarely cytomegalovirus infections are the causes of pathological periostitis^{3,4}.

Traumatic periosteal new bone may be bilateral and multiple, but there is usually other evidence of fracture or hematoma. This new bone is uneven¹. Infantile cortical hyperostosis (ICH) is usually a self-limited disease of infancy with bony changes, soft tissue swelling, fever, irritability, decreased appetite, and decreased movement of the affected bones. The radiographic findings are those of subperiosteal new bone formation of the bones beneath the areas of soft tissue swelling and often elsewhere. These changes have been reported in all portions of the skeletal system except vertebrae³⁻⁵.

In infection, the new bone formation will not affect multiple bones symmetrically and infection markers will be elevated¹. In congenital syphilis, periosteal reaction is seen in long bones and osteochondritis is seen in hand and foot joints. In addition, other clinical manifestations of syphilis such as hepatomegaly, jaundice, hemolytic anemia, thrombocytopenia, stunting, and chorioretinitis may be found and it can be demonstrated serologically⁶.

Our case was evaluated for infection, malignancy and child abuse initially. For child abuse, the infant and his family were evaluated by a social service expert, and it was then excluded

from the diagnosis. As the skeletal findings were extensive and symmetrical, there were no systemic findings, and all hematological, biochemical and microbiologic studies were within normal limits, a physiological (idiopathic) periosteal reaction was considered. Although the long bones were affected evenly, sparing of mandible and clavicles, and no physical findings or history of child abuse led to the diagnosis of physiological periostitis. Radiological findings were normal four months after the diagnosis. This case is presented since physiological periostitis may be a potential pitfall in the differential diagnosis.

REFERENCES

1. Silva P, Evans-Jones G, Wright A, Henderson R. Physiological periostitis; a potential pitfall. *Arch Dis Child* 2003; 88: 1124-1125.
2. Volberg FM, Whalen JP, Krook L, Winchester P. Lamellated periosteal reactions: a radiologic and histologic investigation. *Am J Roentgenol* 1977; 128: 85-87.
3. Ved N, Haller JO. Periosteal reaction with normal-appearing underlying bone: a child abuse mimicker. *Emerg Radiol* 2002; 9: 278-282.
4. Karahan OI, Mavili E, Baykara M, Topaloglu N. Diffuse periosteal elevation due to acquired cytomegalovirus infection. *Erciyes Tip Dergisi* 2003; 25: 166-169.
5. Caksen H, Cesur Y, Odabas D, Aslan H, Rastgeldi L. A case of infantile cortical hyperostosis. *J Nippon Med Sch* 2001; 68: 442-443.
6. Azimi P. Syphilis (*Treponema pallidum*). In: Behrman RE, Kliegman RM, Jenson HB (eds). *Nelson Textbook of Pediatrics* (17th ed). Philadelphia: Saunders; 2004: 978-982.