

## Kabuki make-up syndrome with unilateral renal agenesis

Rasim Özgür Rosti, Hülya Kayserili

Department of Medical Genetics, İstanbul University İstanbul Faculty of Medicine, İstanbul, Turkey

**SUMMARY:** Rosti RÖ, Kayserili H. Kabuki make-up syndrome with unilateral renal agenesis. Turk J Pediatr 2009; 51: 298-300.

Kabuki syndrome is a multiple congenital anomaly/mental retardation syndrome with a diagnosis that is dependent upon clinical findings. Recognition of this entity is based upon unique facial appearance, including long palpebral fissures with everted lower eyelids, arched eyebrows, fleshy-cup-shaped ears and trapezoid philtrum, postnatal growth retardation, and mild to moderate mental retardation. We here report a seven-year, seven-month-old male patient with Kabuki syndrome who also had agenesis of the left kidney. We draw attention to the frequency and diversity of urogenital anomalies in this syndrome.

*Key words:* Kabuki syndrome, multiple congenital anomaly/mental retardation, renal agenesis, eversion of lower eyelid, trapezoid philtrum.

Kabuki (Niikawa-Kuroki) syndrome (KS, MIM 147920) is a multiple congenital anomaly/mental retardation (MCA/MR) syndrome with no direct evidence or clues to clarify the etiology. It was first described independently by Niikawa et al.<sup>1</sup> and Kuroki et al.<sup>2</sup> in 1981. The diagnosis is based on a series of clinical arguments including five cardinal criteria: (1) almost universal facial dysmorphism of arched eyebrows with notched mid-portion and laterally sparse brow hair, long and downwardly slanting palpebral fissures, eversion of the one-third lateral portion of the lower eyelid, squared-off nasal tip, unique configuration of the philtrum that is trapezoidal in shape, cleft lip and/or palate, and fleshy, cup-shaped ears; (2) dermatoglyphic abnormalities; (3) mild to moderate mental retardation; (4) postnatal growth retardation; and (5) skeletal abnormalities.

We report a seven-year, seven-month-old boy with KS with the additional finding of left renal agenesis. This is only the second case with such an association ever to be reported in the literature. We suggest that this may be a further extension to the spectrum of findings, which have been constantly evolving since Niikawa and Kuroki first described the condition, and that renal ultrasonographic examination should be performed in every child diagnosed with KS.

### Case Report

A seven-year, seven-month-old boy was referred to our clinic due to suspicion of Down's syndrome. He was the first child of non-consanguineous Caucasian parents with an unremarkable family history. The pregnancy was complicated with gestational hypertension. He was born by cesarian section due to recorded fetal decelerations at the 33<sup>rd</sup> gestational week. His birth percentiles are unknown. He was discharged from the hospital with satisfactory adaptation on the seventh postnatal day. Left inguinal hernia was noted during the second week of life and right inguinal hernia along with umbilical hernia at two months of age.

Infancy was complicated with bouts of middle ear and urinary tract infections, during which he had two febrile convulsion episodes. Investigations for the etiology of the recurrent urinary tract infections led to the confirmatory finding of left renal agenesis by dimercaptosuccinic acid (DMSA). The patient walked independently at 18 months. One word sentences were accomplished at the age of two and he started to form multi-word sentences at the age of three. He has been receiving special education for the last two years.

On physical examination, anthropometric measurements were all within normal percentiles except height, being well below the third

percentile (105 cm, mean for 4.5 years of age). Facial features, which included arched and laterally sparse eyebrows, prominent eyelashes, long palpebral fissures, lateral eversion of the lateral one-third of the lower eyelid, trapezoidal philtrum, and prominent ears were all suggestive of KS (Fig. 1). He was also noted to have bilateral finger pads, bilateral clinodactyly of the fourth and fifth fingers, brachydactyly, bilateral plantar creases, pectus excavatum and bilateral cubitus valgus. Hyperextensibility of the metacarpophalangeal (MCP) and distal (DIP) and proximal interphalangeal (PIP) joints was observed.

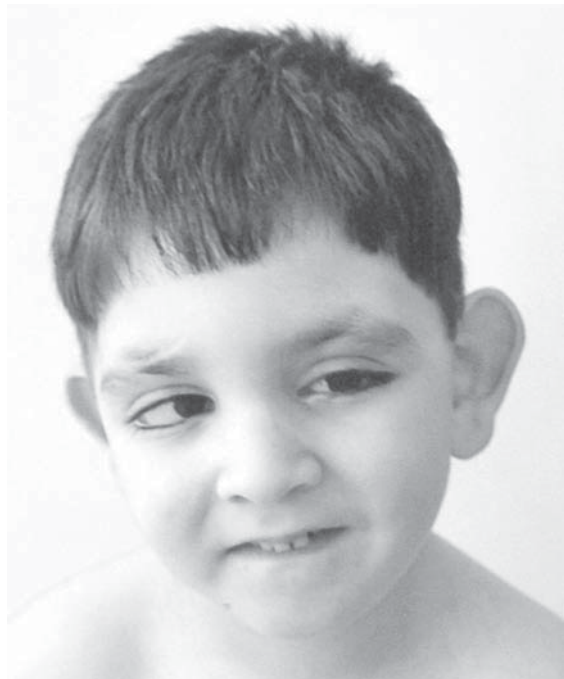

Fig. 1. Facial appearance of the patient. Note the long palpebral fissures with the everted lateral portion of the lower eyelid. (The cicatrix on the right eyebrow is due to a fall during physical activity).

The patient had a normal karyotype (46,XY) and was found to have no abnormalities in ECHO. His BERA test did not show any hearing loss. Other than the left renal agenesis in DMSA, the only major systemic finding was mega cisterna magna observed in cranial imaging (Fig. 2). An assessment of skills at 7 years of age, according to Denver Scale, revealed delayed language and social subscales (mean for 4 and 6 years of age, respectively), with gross and fine motor subscales being normal.

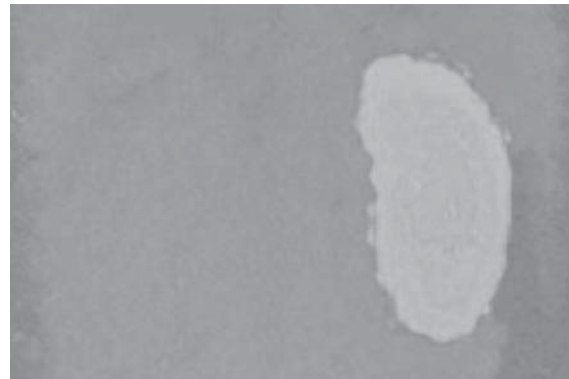


Fig. 2. DMSA showing left renal agenesis (dorsal view).

The clinical diagnosis was established based on the specific facial dysmorphic features of KS.

### Discussion

Kabuki syndrome is named in reference to the traditional make-up that actors of Kabuki, a Japanese theatrical form, apply to their periocular region in order to strengthen their eyes in hero plays, especially when performing as Benkei, the warrior monk; the appearance resembles the facial phenotype of the patients.

Diagnostic handles that prompt the dysmorphologist to consider this diagnosis are mainly in the middle one-third portion of the face. Arched and interrupted eyebrows, long palpebral fissures, lateral eversion of the lower eyelid, depressed nasal tip, broad and protruding philtrum, cleft lip/palate and prominent ears lead to an overall gestalt suggestive of KS<sup>3</sup>. Our patient also displayed all of the hallmark periocular region findings of the syndrome as well as depressed nasal tip, broad and protruding philtrum and prominent ears.

The gestalt, almost universal, is certainly pathognomic if combined with fetal pads. Apart from the unusual dermatoglyphic patterns, clinodactyly and brachydactyly are also observed<sup>4</sup>. Fetal pads, clinodactyly and brachydactyly were also observed features in our case.

Skeletal abnormalities, growth retardation and mental retardation are other accompanying cardinal manifestations of the syndrome<sup>1</sup>. Short stature and a mild to moderate mental retardation were also noted in our patient.

Presently, the ever-evolving spectrum of findings include: cardiovascular anomalies (42%), renal, genital and urinary tract anomalies (28%), joint

laxity (74%), dental abnormalities (68%), susceptibility to infections, especially recurrent otitis media (63%), premature thelarche (28%), hearing loss (27%), inguinal hernia (7%), umbilical hernia (9%) and occasionally neurological abnormalities<sup>5-10</sup>. Our patient demonstrated many of the additional findings, including bilateral inguinal hernias and umbilical hernia, joint laxity, bouts of otitis media and urinary tract infections, and left renal agenesis.

Urogenital anomalies are the frequently seen major system anomalies of KS, second only to cardiovascular system anomalies. They are encountered in one out of four KS patients and have a wide range. Anomalies such as malposition of the kidneys, hydronephrosis, renal hypoplasia, horseshoe kidney, megaureter, and hydroureter were reported. Cryptorchidism, hypospadias and micropenis are also reported frequently<sup>3</sup>. To the best of our knowledge, only one case with renal agenesis has been reported previously<sup>11</sup>.

Although there have been many chromosomal abnormalities reported in KS patients, no identical breakpoints that could lead to the cloning of the putative KS gene were identified. The abundance of familial cases points to possible autosomal dominant inheritance pattern<sup>5</sup>.

To conclude, we propose that renal agenesis is more than just a coincidental finding but rather a continuum to the expanding phenotype of this syndrome. We would also like to underline the importance of renal imaging in KS at the time of diagnosis, since it can reveal major and subtle urogenital anomalies that may be critical in establishing proper patient care.

#### REFERENCES

1. Niikawa N, Matsuura N, Fukushima Y, Ohsawa T, Kajii T. Kabuki make-up syndrome: a syndrome of mental retardation, unusual facies, large and protruding ears, and postnatal growth deficiency. *J Pediatr* 1981; 99: 565-569.
2. Kuroki Y, Suzuki Y, Chyo H, Hata A, Matsui I. A new malformation syndrome of long palpebral fissures, large ears, depressed nasal tip, and skeletal anomalies associated with postnatal dwarfism and mental retardation. *J Pediatr* 1981; 99: 570-573.
3. Adam MP, Hudgins L. Kabuki syndrome: a review. *Clin Genet* 2005; 67: 209-219.
4. Jones KL. *Smith's Recognizable Patterns of Human Malformation* (6<sup>th</sup> ed). Philadelphia: Elsevier; 2006.
5. Matsumoto N, Niikawa N. Kabuki make-up syndrome: a review. *Am J Med Genet* 2003; 117C: 57-65.
6. Erginel A, Tüysüz B, Kartal A, Elçioğlu N. Bir Türk çocuğunda Kabuki-make-up sendromu. *İstanbul Çocuk Kliniği Derg* 1994; 29: 66-70.
7. Çetinkaya E, Mısırlıoğlu ED, Vidinlisan S, Baydar Z, Ozhan ZR. Hypospadias in a patient with Kabuki make-up (Niikawa-Kuroki) syndrome. *J Pediatr Endocrinol Metab* 2001; 14: 803-805.
8. Tutar HE, Ocal G, Ince E, Cin S. Premature thelarche in Kabuki make-up syndrome. *Acta Paediatr Jpn* 1994; 36: 104-106.
9. Say B, McCutcheon L, Todd C, Hough JV. Kabuki make-up syndrome and hearing impairment. *Clin Dysmorphol* 1993; 2: 68-70.
10. Kara B, Kayserili H, Imer M, Çalışkan M, Ozmen M. Quadrigeminal cistern arachnoid cyst in a patient with Kabuki syndrome. *Pediatr Neurol* 2006; 34: 478-480.
11. White SM, Thompson EM, Kidd A, et al. Growth, behavior, and clinical findings in 27 patients with Kabuki (Niikawa-Kuroki) syndrome. *Am J Med Genet* 2004; 127A: 118-127.