

Double-chambered right ventricle mimicking asymmetric septal hypertrophy

Hakan Ceyran¹, Nazmi Narin², Kutay Taşdemir¹, Tevfik Tezcaner¹

Ö. N. Emiroğulları¹, Mustafa Akçakuş²

Departments of ¹Thoracic and Cardiovascular Surgery, and ²Pediatrics, Erciyes University Faculty of Medicine, Kayseri, Turkey

SUMMARY: Ceyran H, Narin N, Taşdemir K, Tezcaner T, Emiroğulları ÖN, Akçakuş M. Double-chambered right ventricle mimicking asymmetric septal hypertrophy. Turk J Pediatr 2003; 45: 80-82.

Double-chambered right ventricle (DCRV) is an uncommon congenital heart disease. Anomalous muscle bundles in the right ventricle divide the right ventricle into two portions and cause intracavitary obstruction of the right ventricle. We report a patient with DCRV mimicking asymmetric septal hypertrophy. We did clinical, echocardiographic and angiographic evaluation. Surgical intervention was successfully managed.

Key words: double-chambered right ventricle, asymmetric septal hypertrophy.

Double-chambered right ventricle (DCRV) is a congenital cardiac anomaly in which the right ventricle is divided into two chambers by anomalous muscle bundles that cross the right ventricular cavity¹⁻⁴. DCRV may be associated with other congenital cardiac anomalies, most commonly with ventricular septal defect and pulmonary stenosis, tetralogy of Fallot, aortic stenosis and regurgitation¹⁻⁵. Here, we report a case of DCRV mimicking asymmetric septal hypertrophy which has not been reported previously.

Case Report

Our case was a 14-year-old girl. Pathologic heart sound was determined in neonatal period but she received insufficient treatment to date due to neglectful parents. She was admitted to the pediatric cardiology department because of fatigue and palpitation. On physical examination she had apical impulse on her chest and 3-4/6 harsh systolic murmur at all cardiac foci. The electrocardiogram showed right and left ventricular hypertrophy. Echocardiography and cardiac angiographic catheterization revealed DCRV, and severe right ventricular obstruction with 105 mm/Hg gradient between inflow and outflow of right ventricle. We also found asymmetric septal hypertrophy. Interventricular septum thickness was 2.85 cm and inter-

ventricular thickness/left ventricular free wall ratio was 2.74 cm, but there was no left ventricular outflow obstruction (Figs. 1, 2, and 3). No evidence of intracardiac shunting or pulmonary stenosis was found. The patient was referred to thoracic and cardiovascular surgery clinic for surgical correction.

She underwent operative correction through a median sternotomy with cardiopulmonary bypass and moderate hypothermia. The right atrium was opened and the right ventricle was

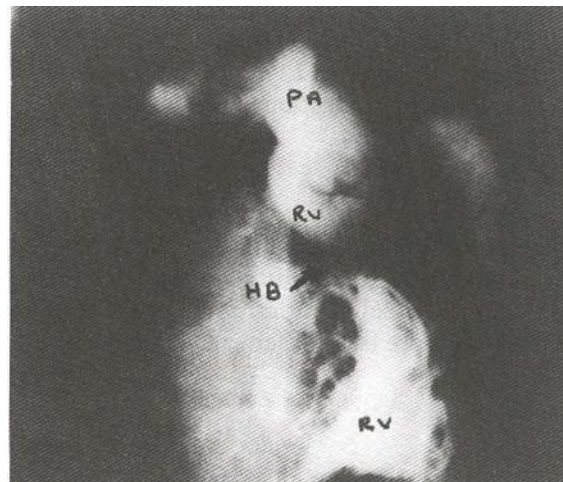


Fig. 1. Angiographic view of the double-chambered right ventricle (PA: pulmonary artery, RV: right ventricle, HB: hypertrophic bundle).

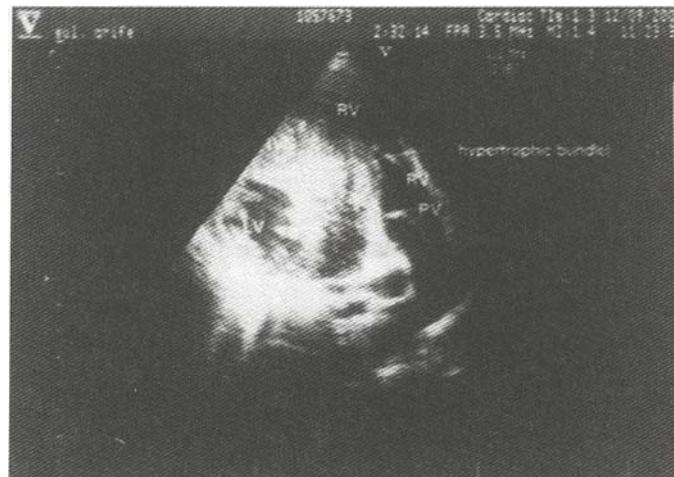

Fig. 2. Echocardiographic pre-operative view of the double-chambered right ventricle (RV: right ventricle, IVS: interventricular septum, LV: left ventricle, PV: pulmonary valve).

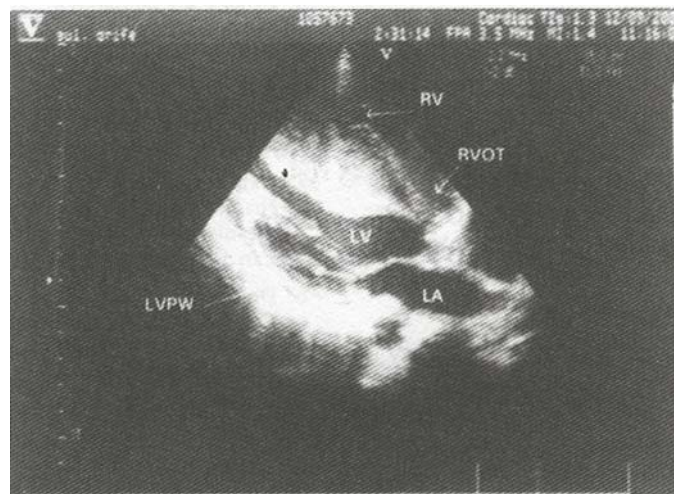


Fig. 3. Echocardiographic pre-operative view of asymmetric septal hypertrophy (RV: right ventricle, RVOT: right ventricle outflow tract, LV: left ventricle, LA: left atrium, LVPW: left ventricle posterior wall).

evaluated through the tricuspid valve. Hypertrophied anomalous muscle at the infundibular region was resected, as were additional hypertrophied septal and parietal muscle bands. The postoperative period was uneventful, and the patient was discharged home on the 8th day. Control echocardiography showed that there was no obstruction in the right ventricle. Postoperative echocardiography demonstrated residual gradients of 10-15 mm Hg across the right ventricular outflow tract. Follow-up at one month revealed our patient in excellent clinical status.

Discussion

Hypertrophic anomalous muscle bands in the right ventricle were noted in 1909, but “double-chambered” right ventricle was first described in 1962 by Lucas et al.⁶ It is characterized by the presence of an anomalous bundle that divides the right ventricle into two chambers and it is a different disease entity from other right ventricular outflow tract obstructive diseases. The anomalous muscle bundles are hypertrophic, constituting a pyramid shaped mass running between the ventricular septum inferior to the insertion site of the tricuspid

valve septal leaflet to the right ventricular anterior free wall. It differs from a moderator band, since the insertion site of a moderator band is in the apical third of the ventricular septum.

The incidence of DCRV is unclear. Forster and Humphries¹ reported one case in 36,000 general autopsies, and there is a 1 to 2.6% incidence in congenital heart diseases. Associated cardiac anomalies are common in DCRV and include ventricular septal defect (VSD) in 56% to 90% of cases, pulmonary stenosis, atrial septal defect, cor triatriatum, and aortic and subaortic stenosis^{1,3,7}. Langes et al.⁵ reported DCRV with left ventricular dysfunction due to hypertrophied right ventricle by a permeable, thick, septum-like structure, creating an additional right ventricle chamber. In our patient we found DCRV associated with abnormal asymmetric interventricular septal hypertrophy. In patients with DCRV, hypertrophy of the right ventricle free wall and interventricular septal hypertrophy are expected findings. But in our case, asymmetric septal hypertrophy was more severe than expected. We could not find any publication with this degree of hypertrophy in the literature. We suppose that the development of abnormal septal hypertrophy secondary to DCRV is strongly possible. Occurrence of DCRV and hypertrophic cardiomyopathy concomitantly in our patient is a weak possibility.

Double-chambered right ventricle (DCRV) traditionally has been repaired transventricularly, but a transatrial approach has been preferred recently, and we also used this procedure. The advantages of transatrial approach are easy visualization of the tricuspid valve leaflets and their attachment, direct visualization of the outflow tract

of the right ventricle and less damage to cardiac tissue. The major complication of the transatrial approach is atrioventricular block^{9,10}. There was no complication in our patient.

Consequently, DCRV mimicking asymmetric septal hypertrophy is an unusual case. Surgical correction of DCRV and associated pathology can be performed with good results.

REFERENCES

1. Forster JW, Humphries JO. Right ventricular anomalous muscle bundles. *Circulation* 1971; 43: 115-127.
2. Simpson WE, Sade RM, Crawford FA, et al. Double-chambered right ventricle. *Ann Thorac Surg* 1987; 44: 7-10.
3. Cil E, Saraçlar M, Özkutlu S, et al. Double-chambered right ventricle. *Int J Cardiol* 1995; 50: 19-29.
4. Hindle MV, Engle MA, Hagstrom JM. Anomalous right ventricular muscles: a clinicopathologic study. *Am J Cardiol* 1968; 21: 487-495.
5. Langes K, Siglow WM, Koschyk D, et al. Double-chambered right ventricle associated with left ventricular dysfunction. *J Thorac Cardiovasc Surg* 1994; 108: 793-794.
6. Lucas RV, Varco RL, Lillehei CW, et al. Anomalous muscle bundle of the right ventricle. *Circulation* 1962; 25: 443.
7. Galal O, Al-Halees Z, Solymar L, et al. Double-chambered right ventricle in 73 patients: spectrum of the disease and surgical results of transatrial repair. *Can J Cardiol* 2000; 16: 167-174.
8. Denfield SW, Gajarski RJ, Towbin JA. Cardiomyopathies. In: Pine JW (ed). *The Science and Practice of Pediatric Cardiology* (2nd ed) Vol II. Pennsylvania: Williams and Wilkins; 1998: 1861-1870.
9. McElhinney DB, Chatterjee KM, Reddy MV. Double-chambered right ventricle presenting in adulthood. *Ann Thorac Surg* 2000; 70: 124-127.
10. Ford DK, Bullaboy CA, Derkac WM, et al. Transatrial repair of double-chambered right ventricle. *Ann Thorac Surg* 1988; 46: 412-415.