

A case of spontaneous rupture of the bladder

Christos Limas¹, Chrisostomos Soultanidis¹, Savvas Deftereos²

Mariana Skordala³, Joannis Sigalas³

Departments of ¹Pediatric Surgery, ²Radiology, and ³Neonatology, University General Hospital of Alexandroupolis, Alexandroupolis Greece

SUMMARY: Limas C, Soultanidis C, Deftereos S, Skordala M, Sigalas J. A case of spontaneous rupture of the bladder. Turk J Pediatr 2007; 49: 196-198.

Rupture of the bladder in the neonatal period followed by urinary ascites is rare and usually the result of umbilical artery catheterization. Patients may present with abdominal distension, oliguria or anuria, and signs of renal insufficiency. We present a case of urinary ascites in a premature neonate due to a spontaneous rupture of the bladder, and we discuss the pathogenesis, diagnosis and management of this case.

Key words: urinary ascites, rupture of the bladder, neonate.

Urinary ascites due to the rupture of the bladder in the neonatal period is rare and only a few cases have been described in the literature¹. The majority are the results of umbilical arterial catheterization causing rupture of the dome of the bladder or of a patent urachus. The posterior urethral valves in male neonates and the congenital diverticulum of the bladder may be predisposing anatomical factors for rupture of the bladder². Spontaneous rupture of the bladder has also been reported in the literature as a result of profound hypoxia or morphine administration³, though ruptures may also occur without clear predisposing factors and are presumably associated with obstructive uropathy, abdominal trauma, neurogenic bladder, iatrogenic injuries during endoscopic or open surgical procedures, birth trauma, difficult obstetric delivery, urethral catheterization and umbilical catheterization^{4,5}. Extravasation of the urine into the peritoneal cavity is life threatening, as the urine undergoes "autodialysis" by the peritoneal membrane and produces a particular biochemical profile in serum that, in combination with ascites, should lead the clinician to suspect a disruption of the urinary tract³. Suggested management is dependent upon the mode of injury and whether the defect is intraperitoneal or extraperitoneal. In either case, identification of the injury and treatment by either an operation or catheter drainage may be lifesaving⁶. Although a rare condition, infants with urinary ascites can

present as clinical emergencies in need of prompt resuscitation with subsequent drainage of the urine and decompression of the urinary tract⁷.

Case Report

A premature female neonate, weighing 1500 g, was born at the 32nd week of gestation with vaginal delivery. The antenatal course was uneventful. Apgar scores were 6 at 1 minute and 7 at 5 minutes. The neonate developed respiratory distress soon after the delivery and was intubated. Morphine was administered for ventilatory sedation.

As of the second day of life, a little amount of viscous meconium had been passed and the abdomen was markedly distended. The abdominal upright X-ray revealed absence of air in the distal colon and the condition was attributed to a meconium plug. The distension was relieved by a rectal enema of acetylcysteine. The 6th day micturition was ceased and the abdominal distension developed again followed by electrolytic disturbances such as hyponatremia, hyperkalemia and elevated serum creatinine. The abdominal X-ray revealed the presence of ascitic fluid in the abdomen (Fig. 1). The insertion of a bladder catheter drained a large amount of urine and the abdominal distension was relieved, raising the suspicion of urinary ascites. Echographically, the kidneys were detected with hyperechogenicity, a sign indicating renal

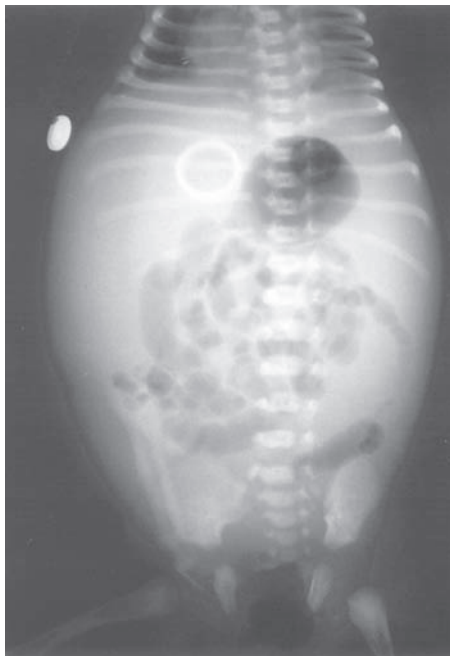

Fig. 1. Abdominal X-ray reveals the presence of ascitic fluid in the abdomen.

insufficiency. The cystogram detected a diffuse extravasation of the contrast material in the peritoneal cavity, confirming the diagnosis of a urinary ascites due to the bladder rupture (Fig. 2). Conservative management with bladder catheterization was decided as initial treatment. The neonate's clinical condition and

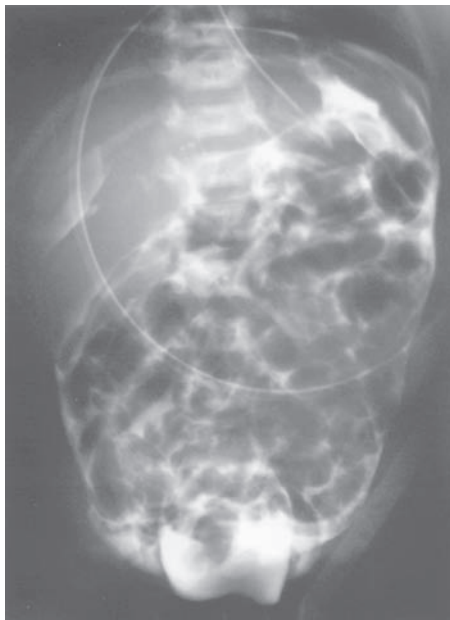


Fig. 2. Diffuse extravasation of the contrast material in the peritoneal cavity.

renal function were improved and there was no re-accumulation of ascitic fluid until the 11th day. Abdominal distension developed again the next day with aggravation of the neonate's clinical condition. Surgical repair of the bladder rupture was then imperative. Exploration of the bladder revealed a laceration of 2 cm in the posterior and left lateral wall leaving the ureter intact. The ascitic fluid was drained via the rupture, the ureteral orifices were identified and their patency was confirmed. The lesion was repaired with interrupted absorbable stitches in two layers and the bladder was drained by suprapubic cystostomy. No other anatomical defect of the bladder was detected. On the 10th postoperative day the cystogram via cystostomy was normal and the suprapubic tube was removed.

Discussion

Ascites in the neonatal period is a rare condition, and for less than 30% of cases urinary ascites is implicated⁸. The spontaneous or iatrogenic intraperitoneal rupture of the bladder is responsible for this condition. The presence of posterior urethral valves in male neonates is one of the most common causes of spontaneous rupture of the bladder. The congenital diverticulum of the bladder may predispose to the bladder rupture⁹. The prolonged exposure to hypoxia that leads to ischemic visceral damage may also cause ischemic lesions to the bladder, which may lead to the rupture. Umbilical arterial catheterization causing trauma to the dome of the bladder or to a patent urachus accounts for 75% of bladder ruptures¹⁰. The Foley-catheter has also been reported to induce rupture^{11,12}. Morphine administration can cause urinary retention, which may lead to the rupture of the bladder³. Among ruptures associated with umbilical arterial cannulation, the mortality rate is 18%¹⁰. Urinary bladder perforation should be considered in a case of neonatal ascites with renal failure, which is unexplainable by other causes¹³. Some cases of congenital bladder perforation and urinary ascites have been diagnosed in utero^{14,15}.

The diagnosis of ascites is made by abdominal X-ray or ultrasound, but it is difficult to determine the origin of the ascitic fluid. Initial radiographic studies should include a plain abdominal film, which characteristically reveals

a ground glass appearance with enteric loops in the mid abdomen¹. The association of anuria or oliguria, with hyponatremia, hyperkalemia and elevation of serum creatinine in addition to ascites must lead to the diagnosis of the urinary ascites¹¹. Ultrasound in some cases may reveal the lesion to the wall of the bladder. In the remainder of cases, the extravasation into the peritoneal cavity of a contrast material infused into the bladder via a transurethral catheter will confirm the diagnosis. In patients with urinary ascites, paracentesis will reveal straw-colored fluid.

Conservative management with a catheter drainage of the bladder for 10-14 days leads to complete healing of the lesion in most cases. Large ruptures do not respond to the conservative management and a surgical repair is required. Operative management includes examination of the inner aspect of the bladder, closure of the rupture with multiple absorbable layers and placement of cystostomy. The identification and preservation of the patency of the ureteral orifices is mandatory during the repair.

In our case, the etiology of the rupture of the bladder was unknown. During the operative exploration no anatomical defect was identified as capable of inducing rupture of the bladder. There also was no previous attempt of bladder or umbilical vessel catheterization. Hypoxia that developed was mild and there was no sign of injury to organs more vulnerable to hypoxia than the bladder. The administration of morphine, for ventilatory sedation, and the consecutive urinary retention, is a predisposing factor that can be blamed for the rupture of the bladder.

In conclusion, in an infant with ascites, oliguria or anuria and signs of renal insufficiency, the diagnosis of urinary ascites is likely and must be confirmed by ultrasound and cystogram. Healing of the lesion is achievable with conservative management, but in cases where the extravasation of urine persists, a surgical repair is indicated.

REFERENCES

1. Trulock TS, Finnerty DP, Woodard JR. Neonatal bladder rupture: case report and review of literature. *J Urol* 1985; 133: 271-273.
2. Arora P, Seth A, Bagga D, Aneja S, Taluja V. Spontaneous bladder rupture secondary to posterior urethral valves in a neonate. *Indian J Pediatr* 2001; 68: 881-882.
3. Oei J, Garvey PA, Rosenberg AR. The diagnosis and management of neonatal urinary ascites. *J Paediatr Child Health* 2001; 37: 513-515.
4. Claahsen-van der Grinten HL, Monnens LA, de Gier RP, Feitz WF. Perinatal rupture of the uropoietic system. *Clin Nephrol* 2002; 57: 432-438.
5. Sayan A, Demircan M, Erikci VS, Çelik A, Arikan A. Neonatal bladder rupture: an unusual complication of umbilical catheterization. *Eur J Pediatr Surg* 1996; 6: 378-379.
6. Roth DR, Krueger RP, Barraza M. Bladder disruption in the premature male neonate. *J Urol* 1987; 137: 500-501.
7. Checkley AM, Sabharwal AJ, MacKinlay GA, Munro FD, Orr JD. Urinary ascites in infancy: varied etiologies. *Pediatr Surg Int* 2003; 19: 443-445.
8. Kaplan WG, McAleer MI. Structural abnormalities of the genitourinary system. In: Avery GB, Fletcher MA, Macdonald GM (eds). *Neonatology Pathophysiology and Management of the Newborn* (5th ed). Philadelphia: JB Lippincott Co.; 1999: 975-1003.
9. Redman JF, Seibert JJ, Arnold W. Urinary ascites in children owing to extravasation of urine from the bladder. *J Urol* 1979; 122: 409-411.
10. Diamond DA, Ford C. Neonatal bladder rupture: a complication of umbilical artery catheterization. *J Urol* 1989; 142: 1543-1544.
11. Morrell P, Coulthard MG, Hey EN. Neonatal urinary ascites. *Arch Dis Child* 1985; 60: 676-678.
12. O' Brien WJ, Ryckman FC. Catheter induced urinary bladder rupture presenting with pneumoperitoneum. *J Pediatr Surg* 1994; 29: 1397-1398.
13. Basha M, Subhani M, Mersal A, Saedi SA, Balfe JW. Urinary bladder perforation in a premature infant with Down syndrome. *Pediatr Nephrol* 2003; 18: 1189-1190.
14. Bettelheim D, Pumberger W, Deutinger J, Bernaschek G. Prenatal diagnosis of fetal urinary ascites. *Ultrasound Obstet Gynecol* 2000; 16: 473-475.
15. Lowenstein L, Solt I, Talmon R, Pery M, Suhov P, Drugan A. In utero diagnosis of bladder perforation with urinary ascites. A case report. *Fetal Diagn Ther* 2003; 18: 179-182.