

## Peritoneal tuberculosis with elevated serum CA 125 level mimicking advanced ovarian carcinoma in an adolescent

Funda Çorapçioğlu<sup>1</sup>, B. Haluk Güvenç<sup>2</sup>, Nazan Sarper<sup>1</sup>, Ayşen Aydoğan<sup>1</sup>

Gür Akansel<sup>3</sup>, Emin Sami Arısoy<sup>1</sup>

Departments of <sup>1</sup>Pediatrics, <sup>2</sup>Pediatric Surgery, and <sup>3</sup>Radiology, Kocaeli University Faculty of Medicine, Kocaeli, Turkey

**SUMMARY:** Çorapçioğlu F, Güvenç BH, Sarper N, Aydoğan A, Akansel G, Arısoy ES. Peritoneal tuberculosis with elevated serum CA 125 level mimicking advanced ovarian carcinoma in an adolescent. Turk J Pediatr 2006; 48: 69-72.

Differential diagnosis between tuberculous peritonitis and peritonitis carcinomatosis is extremely difficult in patients with ascites, peritoneal implants and elevated CA 125 level. A 16-year-old girl presented with abdominal distention, intermittent fever and weight loss. Physical examination and radiologic studies revealed massive ascites, generalized peritoneal thickening and slightly enlarged right ovary with a cystic mass and left pleural effusion. Serum CA 125 was 939 U/L (normal range: 0-35 U/L) and other tumor markers including alpha fetoprotein (AFP) and  $\beta$ -human chorionic gonadotropin (HCG) were within normal range. Acid-fast stain and culture were negative for Mycobacterium tuberculosis. Diagnostic laparoscopy and biopsy were performed with the presumptive diagnosis of peritonitis carcinomatosis, and histologic examination revealed multiple granulomas with epithelioid cells and caseification necrosis which confirmed tuberculosis. Quadruple anti-tuberculosis treatment was administered and the patient's clinical findings and serum CA 125 level returned to normal. In conclusion, tuberculous peritonitis should be considered in the differential diagnosis of patients with ascites and elevated serum CA 125. This marker may be useful in monitoring treatment response.

*Key words:* tuberculous peritonitis, CA 125, adolescent.

Tuberculous peritonitis and peritonitis carcinomatosis share common clinical and radiologic findings<sup>1,2</sup>. Increased serum level of CA 125 is a useful marker of epithelial ovarian cancer but can also increase in inflammatory conditions including peritoneal tuberculosis<sup>3-5</sup>. Occasionally, differential diagnosis between tuberculous peritonitis and peritonitis carcinomatosis is extremely difficult in a patient with ascites, peritoneal implants and elevated CA 125 level<sup>6,7</sup>. Frequently, Mycobacterium tuberculosis cannot be isolated and the diagnosis is based on histologic confirmation<sup>2,4,8</sup>. Patients with peritoneal tuberculosis are misdiagnosed as having ovarian malignancy and are subjected to unnecessary extended surgery<sup>6</sup>. We present an adolescent girl with tuberculous peritonitis and elevated serum CA 125 level in whom the diagnosis was confirmed with laparoscopic and histologic examination.

### Case Report

A 16-year-old girl was referred to our center with a two-month history of malaise, abdominal distention, intermittent fever and weight loss of 4 kg. The previous medical history of the patient and her family was not significant for tuberculosis and she had vaccination for M. tuberculosis during early infancy. She was admitted to an internal medicine outpatient clinic three days previously where abdominal ultrasonography was performed and serum CA 125 was measured. Ascites and a cystic mass on the right ovary were observed and serum CA 125 level was elevated to 939 U/L (normal range 0-35 U/L). She was referred to the pediatric oncology unit with a provisional diagnosis of advanced stage ovarian carcinoma. On physical examination, a nontender, distended abdomen, moderate ascites, and no palpable mass were noted, and respiratory sounds

were diminished on the left lower lung field. Complete blood count showed hemoglobin 10.1 g/dl, white blood cell 6450/ $\mu$ L and platelets 477,000/ $\mu$ L, and erythrocyte sedimentation rate was 120 mm/h. Serum biochemistry was normal except for elevated aspartate aminotransferase (106 U/L) and alanine aminotransferase (103 U/L) levels. Serologic examination for hepatitis A, B or C infection was negative. Alpha fetoprotein (AFP) and  $\beta$ -human chorionic gonadotropin ( $\beta$ -HCG) levels were also within normal range. Abdominal magnetic resonance imaging (MRI) revealed massive ascites, generalized peritoneal thickening without septation and a slightly enlarged right ovary (41x30 mm) with a cystic mass 14x14 mm in diameter (Figs. 1a and 1b). Chest X-ray

and thorax computerized tomography (CT) showed left pleural effusion without pulmonary parenchymal lesion. Diagnostic thoracentesis and paracentesis yielded a mononuclear cell-rich exudative fluid with negative Gram and acid-fast stains. Characteristics of ascitic fluid included: total protein 6.4 g/dl, lactate dehydrogenase (LDH) 531 U/L, glucose 56 mg/dl (simultaneous blood glucose 103 mg/dl), ascites protein/serum protein=0.7 and ascites LDH/serum LDH=1.46. Characteristics of pleural fluid were similar to ascites. There was no malignant cell in cytologic examination of ascites and pleural fluid. *M. tuberculosis* cultures (BacTec and Löwenstein-Jensen medium) of ascites and pleural fluid remained sterile. Polymerase chain reaction (PCR) analysis for *M. tuberculosis* was not available. A tuberculin skin test was negative with 9x9 mm induration in 72 hours. Adenosine deaminase (ADA) levels of pleural and peritoneal fluids were within normal range, 17.8 and 18.9 U/L, respectively (normal level of ADA <40 U/L)<sup>9,10</sup>. Diagnostic laparoscopy, which was performed with the preoperative presumptive diagnosis of peritonitis carcinomatosa, revealed diffuse multiple nodules over the whole peritoneum with adhesion between omentum and peritoneum (Fig. 2). The right ovary was slightly enlarged and contained a cyst. Biopsy samples were obtained from peritoneum, right ovary, cystic mass and fallopian tube. Histologic examination revealed multiple granulomas with epithelioid cells and caseification necrosis in all samples, and cystic mass was identified as luteinized cyst (Fig. 3). The caseating

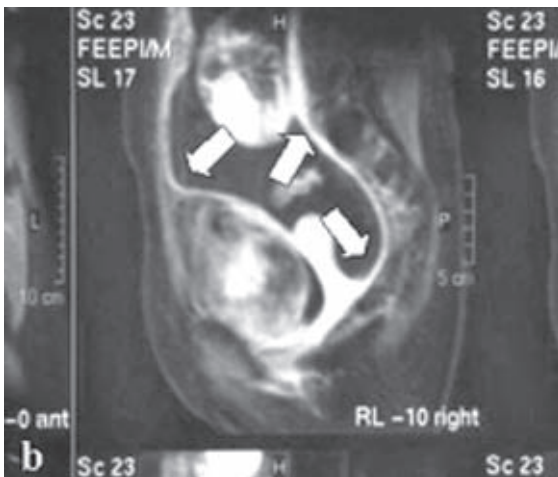
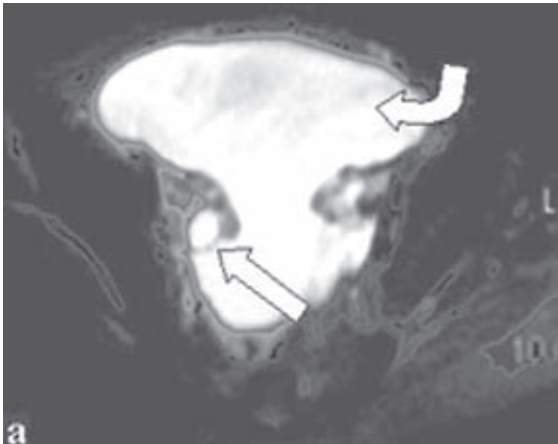


Fig. 1a-1b. a) Axial T2-weighted image. Right ovarian cyst (straight arrow) and ascites (curved arrow). b) Postcontrast fat-suppressed T1-weighted sagittal image. Abnormal contrast enhancement of peritoneal surfaces (arrows).

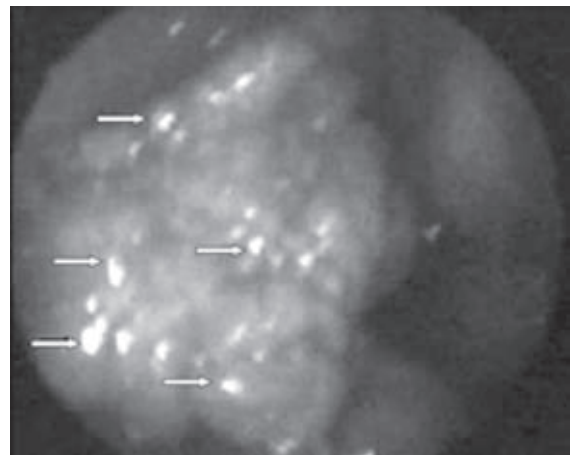


Fig. 2. Multiple nodules over the peritoneal wall (arrows).

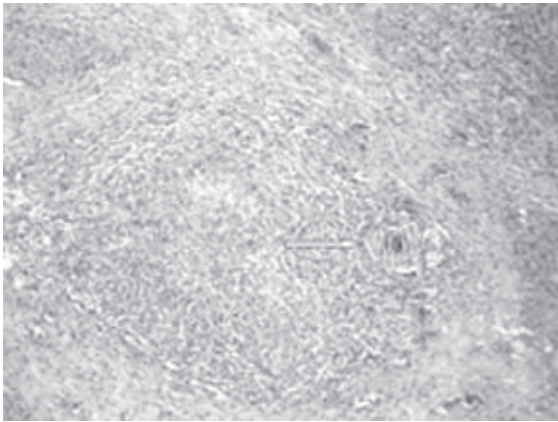


Fig. 3. Epithelioid granuloma in the peritoneal biopsy specimen (arrow).

granulomatous pattern was consistent with tuberculosis; however, all cultures of these specimens were negative for tuberculosis. Quadruple anti-tuberculosis treatment with rifampicin 600 mg/day, pyrazinamide 2 g/day, streptomycin 1 g/day and isoniazid 300 mg/day was started. Streptomycin and pyrazinamide were ceased at the end of the first and second month of therapy, respectively. A 12-month therapy with the other two drugs was planned. The patient's fever and abdominal distention regressed at the end of the 2<sup>nd</sup> week of therapy. Follow-up measurement of serum CA 125 in the 3<sup>rd</sup> month of anti-tuberculous treatment showed a significant decrease (9.4 U/L). She is in the 4<sup>th</sup> month of the treatment and has no evidence of the disease.

### Discussion

Clinical presentation of the patient was typical for peritoneal carcinomatosis, which is rare in children. Peritoneal metastases may be associated with a wide variety of childhood tumors<sup>1,11</sup>. In contrast to adults, two-thirds of pediatric ovarian tumors are of germ cell origin, and some germ cell tumors with identifiable malignant elements produce measurable amounts of serum AFP or  $\beta$ -HCG<sup>12</sup>. Malignancies originating from epithelial or stromal cells are uncommon in children. Serum CA 125 level is a useful marker of epithelial ovarian cancer; it is secreted from the mesothelial cells lining the peritoneum, pleura, pericardium, and areas of inflammation<sup>3-5</sup>. Inflammatory and benign conditions or malignant conditions including

acute leukemia and non-Hodgkin's lymphoma with serosal involvement and gastric carcinoma can cause elevation of CA 125<sup>13-16</sup>.

Serum CA 125 level was more than 1000 U/L in 89% of gynecological cancers. In most reported cases of peritoneal tuberculosis, serum CA 125 levels were <500 U/L, but very high levels (>1000 U/L) have been reported in some patients with peritoneal tuberculosis<sup>3,4,6,17</sup>. In the presented case, the level of CA 125 was >500 U/L, which is similar to reported patients with tuberculosis.

Abdominal tuberculosis is one of the most prevalent forms of extrapulmonary disease and a significant problem due to poor environmental and socioeconomic conditions<sup>4,8</sup>. Peritoneal tuberculosis may present with nonspecific signs and symptoms such as ascites and abdominal pain and mass, and may mimic ovarian cancer<sup>3,7</sup>. Ultrasound examination and CT scanning of the abdomen and pelvis may have limited value in the differential diagnosis between disseminated intraabdominal ovarian carcinoma and abdominal tuberculosis. Even during laparoscopy or laparotomy, the macroscopic findings of peritoneal tuberculosis may be similar to disseminated intraabdominal ovarian carcinoma<sup>6,17</sup>. In the presented case, clinical presentation and radiological findings mimicked ovarian carcinoma.

Various investigations had been reported as the gold standard of diagnosis of tuberculous peritonitis<sup>8</sup>. However, the diagnosis of tuberculosis is still difficult in the clinical setting. Although the diagnosis of tuberculosis requires microbiological confirmation, the diagnosis of extrapulmonary tuberculosis is frequently based on histopathologic investigation<sup>2,8</sup>. The incidence of microbiologic isolation of the agent in ascitic fluid is under 50% in abdominal tuberculosis<sup>8</sup>. Negative skin test results were no guarantee of the effusion being nontuberculous<sup>18</sup>. The isolation of *M. tuberculosis* with BacTec or PCR may be helpful in obtaining results earlier, but even these methods appear to be far from ideal<sup>7,8</sup>. Estimation of ADA level in ascitic fluid is an easy and reliable method in confirming diagnosis of the peritoneal tuberculosis<sup>2,9,10</sup>. In the presented case, *M. tuberculosis* was not confirmed with microbiological investigation, and the diagnosis was based on histopathologic

findings of laparoscopic biopsy samples. Pleural fluid was considered as a reaction of abdominal tuberculosis and ascites.

Laparoscopic observation and biopsies obtained from the peritoneum have been reported to be more helpful, and these findings may be used for diagnosis<sup>4,6,8</sup>. If no malignancy is detected and the diagnosis of peritoneal tuberculosis is confirmed, unnecessary extended surgery is avoided and anti-tuberculous treatment is started<sup>2,6,8</sup>. On the other hand, the possibility of port-site metastasis, which is a common complication consecutive to laparoscopic management in patients with gynecologic cancer and ascites, must always be kept in mind<sup>19</sup>.

Serum CA 125 level can be used for monitoring response to anti-tuberculous treatment<sup>6</sup>. In our patient, serum CA 125 level also decreased to normal level after treatment, similar to reported cases<sup>3,7</sup>.

In conclusion, tuberculous peritonitis should be considered in the differential diagnosis of a patient with ascites and elevated serum CA 125. Patients with peritoneal tuberculosis may be misdiagnosed as ovarian malignancy and subjected to unnecessary extended surgery. Acid-fast stain and special cultures of the ascitic fluid for *M. tuberculosis* are frequently negative, and confirmation of the diagnosis requires histologic examination of the biopsy specimens. This report confirms that elevation of CA 125 level may be associated with peritoneal tuberculosis. Serial measurements of CA 125 may be useful in monitoring treatment response.

#### REFERENCES

- Shibata R, Matsufuji H, Morimoto T, Araki A, Hata J. Extraovarian primary peritoneal carcinoma in a child. *Pediatr Blood Cancer* 2004; 42: 292-293.
- Protopapas A, Milingos S, Diakomanolis E, et al. Miliary tuberculous peritonitis mimicking advanced ovarian cancer. *Gynecol Obstet Invest* 2003; 56: 89-92.
- Wu JF, Li HJ, Lee PI, Ni YH, Yu SC, Chang MH. Tuberculous peritonitis mimicking peritonitis carcinomatosis: a case report. *Eur J Pediatr* 2003; 162: 853-855.
- Straughn JM, Robertson MW, Partridge EE. A patient presenting with a pelvic mass, elevated CA-125, and fever. *Gynecol Oncol* 2000; 77: 471-472.
- Giordano S, Miglionico L, Pellegrino M, De Meco C, Sciannone N, Castricola Scanderberg A. [Hydronephrosis associated with elevated serum levels of CA 125 antigen. Report of a case.] [Italian]. *Mineura Pediatr* 1996; 48: 333-335.
- Mpiura B, Rabinovich A, Leron E, Yanai-Inbar I, Mazor M. Peritoneal tuberculosis - an uncommon disease that may deceive the gynecologist. *Eur J Gynecol Oncol* 2003; 110: 230-234.
- Bilgin T, Karabay A, Dolar E, Develioglu OH. Peritoneal tuberculosis with pelvic abdominal mass, ascites and elevated CA 125 mimicking advanced ovarian carcinoma: a series of 10 cases. *Int J Gynecol Cancer* 2001; 11: 290-294.
- Bayramiçli-Uygur O, Dabak G, Dabak R. A clinical dilemma: abdominal tuberculosis. *World J Gastroenterol* 2003; 9: 1098-1101.
- Haro M, Ruiz Manzano J, Morera J, Gallego M, Manterola JM, Ribas J. [Analysis of 90 cases of pleural tuberculosis in relation to adenosine deaminase levels] [Spanish]. *Med Clin (Barc)* 1997; 108: 452-454.
- Valdes L, San Jose E, Alvarez D, Valle JM. Adenosine deaminase (ADA) isoenzyme analysis in pleural effusions: diagnostic role, and relevance to the origin of increased ADA in tuberculous pleurisy. *Eur Resp J* 1996; 9: 747-751.
- Kaste SC, Marina N, Fryrear R, et al. Peritoneal metastasis in children with cancer. *Cancer* 1998; 83: 385-390.
- Castleberry RP, Cushing B, Perlman EJ, Hawkins EP. Germ cell tumors. In: Pizzo PA, Poplack DG (eds). *Principles and Practice of Pediatric Oncology* (3rd ed). Philadelphia: Lippincott-Raven Publishers; 1997: 921-946.
- Candocia SA, Locker GY. Elevated serum CA-125 secondary to tuberculous peritonitis. *Cancer* 1993; 72: 2016-2018.
- Gungor T, Parlakyigit EE, Dumanlı H. Actinomycotic tubo-ovarian abscess mimicking pelvic malignancy. *Gynecol Obstet Invest* 2002; 54: 119-121.
- Camera A, Villa MR, Rocco S, et al. Increased CA 125 serum levels in patients with advanced acute leukemia with serosal involvement. *Cancer* 2000; 88: 75-78.
- Kutluk T, Varan A, Erbaş B, Büyükpamukcu M. Serum CA 125 levels in children with non-Hodgkin's lymphoma. *Pediatr Hematol Oncol* 1999; 16: 311-319.
- Gurgan T, Zeyneloğlu H, Urman B, Develioglu O, Yarı H. Pelvic-peritoneal tuberculosis with elevated serum and peritoneal fluid Ca-125 levels. A report of two cases. *Gynecol Obstet Invest* 1993; 35: 60-61.
- Valdes L, Alvarez D, San Jose E, et al. Tuberculous pleurisy: a study of 254 patients. *Arch Intern Med* 1998; 158: 2017-2021.
- Lecuru F, Darai E, Robin F, Housset M, Durdax C, Taurelle R. Port site metastasis after laparoscopy for gynecological cancer: report of two cases. *Acta Obstet Gynecol Scand* 2000; 79: 1021-1023.