

Role of scintigraphy in congenital thyroid anomalies

Bilge Volkan Salancı, Pınar Özgen Kıratlı, Emel Ceylan Günay

Department of Nuclear Medicine, Hacettepe University Faculty of Medicine, Ankara, Turkey

SUMMARY: Salancı BV, Kıratlı PÖ, Günay EC. Role of thyroid scintigraphy in congenital thyroid anomalies. Turk J Pediatr 2005; 47: 364-368.

Thyroid scintigraphy using Tc-99m pertechnetate is a frequently performed procedure in routine nuclear medicine practice. The indications for thyroid scintigraphy are investigation of hyperthyroidism, nodularity of the gland, cause of thyroid stimulating hormone elevation and localization of an ectopic thyroid gland. In the pediatric population, the most common request is for the evaluation of neonatal hypothyroidism. This imaging procedure is helpful in the identification of the underlying cause as well as in making a differential diagnosis. Early diagnosis is essential for appropriate therapy planning in this age group, and thyroid scintigraphy provides important diagnostic data. This article is written to review the scintigraphic findings in various congenital thyroid anomalies and to underline its use in the differential diagnosis.

Key words: thyroid scintigraphy, Tc-99m pertechnetate, neonatal hypothyroidism.

Thyroid scintigraphy using Tc-99m pertechnetate is a routine diagnostic procedure in the evaluation of thyroid nodules and the etiology of hyperthyroidism¹. Other indications are investigation of retrosternal and anterior neck masses as well as determination of ectopic tissue. Evaluation of congenital hypothyroidism with elevated thyroid-stimulating hormone (TSH) is the most common indication in the pediatric population. The three main causes of neonatal hypothyroidism are dysembryogenesis, dyshormonogenesis and transient hypothyroidism. Dysembryogenesis includes agenesis and/or ectopic tissue², whereas the term dyshormonogenesis indicates enzyme defects causing lack of iodine uptake or organogenesis. Transient hypothyroidism is observed rarely and the main cause is maternal blocking antibodies³.

Although thyroid scintigraphy is performed very often, some rare scintigraphic patterns of congenital thyroid gland anomalies should be kept in mind. The authors of this work aimed to review the rarely seen scintigraphic patterns in patients with neonatal hypothyroidism.

Case Reports

Case 1

Congenital thyroid agenesis

An elevated TSH level (TSH: >100 uIU/ml) on screening test was found in a 20-day-old male patient. His thyroid hormone levels were below

normal: T4: 0.71 ng/dl (N:4.87-11.72 ng/dl), free T4: 0.01 pmol/L (N:9-19.04 pmol/L). He was referred to the Nuclear Medicine Department for thyroid scintigraphy to rule out agenesis. The thyroid scintigraphy using Tc-99m pertechnetate showed absence of his gland. A consecutive ultrasonographic examination confirmed this finding so thyroid hormone replacement was initiated (Figs. 1a, 1b).

Case 2

Ectopic Thyroid Gland

A 15-day-old male patient had TSH elevation on screening test for congenital hypothyroidism. His thyroid hormone levels were below the normal limits (T4: 1.64 ng/dl, free T4: 3.49 pmol/L) and he was referred for thyroid scintigraphy, which revealed that the thyroid gland was not localized in the neck, but at the sublingual region (Figs. 2a, 2b). Thyroid replacement therapy was initiated immediately.

Case 3

Functional Thyroid Tissue in Thyroglossal Cyst

A 16-year-old female patient complaining of fatigue was admitted to the hospital. On physical examination a palpable mass lesion was found in the neck inferior to the hyoid bone. On her thyroid function tests a slight depression of TSH and normal T3 and T4 levels were found. On ultrasonography (US), the dimensions of the right lobe were 27x16x37



Fig. 1. Anterior projection of a thyroid gland scintigraphy performed on a 20-day-old boy, showing non-visualization of the thyroid gland (a). Whole body imaging is performed in order to reveal ectopic gland localization (b).



Fig. 2a. Thyroid scintigraphy with ^{99m}Tc pertechnetate of 15-day-old boy revealed uptake of radioactivity in the midline, superior to the thyroid gland lodge.

Fig. 2b. On the lateral view, the markers (X: chin, Y: mandible angle) defined the exact localization of the gland.

mm and of the left lobe 20x18x37 mm. Multiple millimetric nodules were noted in both lobes, with the largest one in the left lobe, measuring 12x7x12 mm. A hypoechoic mass lesion of 15x10x19 mm was observed in front of the larynx. The patient was referred for thyroid scintigraphy to evaluate the nature of the nodules. Scintigraphy revealed a hyperactive nodule on the left lobe and focal uptake of radioactivity superior to the thyroid gland in the midline, which was concordant with the palpable mass (Fig. 3). The patient underwent bilateral subtotal thyroidectomy and thyroglossal cyst excision. The pathologic examination of the surgical specimen revealed multiple thyroid adenomas and normal thyroid follicular cells in the thyroglossal cyst.

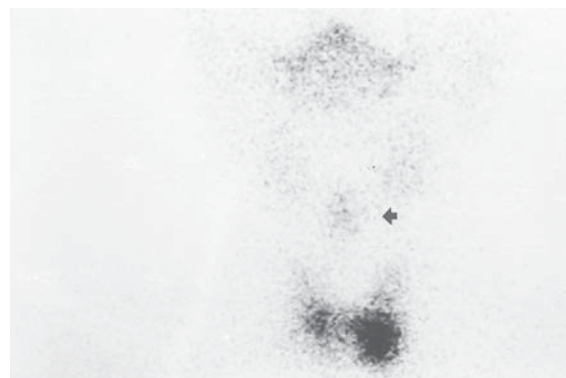


Fig. 3. The thyroid scintigraphy in a 46-year-old female patient demonstrated a hyperactive nodule in the left thyroid lobe as well as a focal uptake of radioactivity (arrow) in the midline superior to the thyroid gland, which was concordant with the palpable mass.

Case 4

Thyroid stimulating hormone elevation due to maternal antibodies

A six-month-old male patient had persistent elevated TSH levels (7.22 uIU/ml and 4.9 uIU/ml at different time points), with normal thyroid hormone levels (T4: 10.52 ug/dl and free T4: 11.37 pmol/ml, thyroglobulin: 44 ng/ml). Slightly exaggerated response was obtained at TRH stimulation test. The TSH levels at 20, 40, 60 and 90 minutes were 31.67 uIU/ml, 30.9 uIU/ml, 25.05 uIU/ml and 17.11 uIU/ml, respectively. He was referred for thyroid scintigraphy. His thyroid gland was not visualized on the scan. This was an unexpected finding and the patient was referred for thyroid US, which revealed normal thyroid gland. The left thyroid lobe was measured as 18x6x7 mm and the right lobe as 18x7x7 mm. His mother's antimicrosomal antibodies were elevated. The thyroid scintigraphy was repeated two months later when the patient was eight months of age, at which time minimal uptake of radioactivity was observed in the thyroid lodge, which supported the suppressive effect of maternal blocking antibodies (Figs. 4a, 4b).

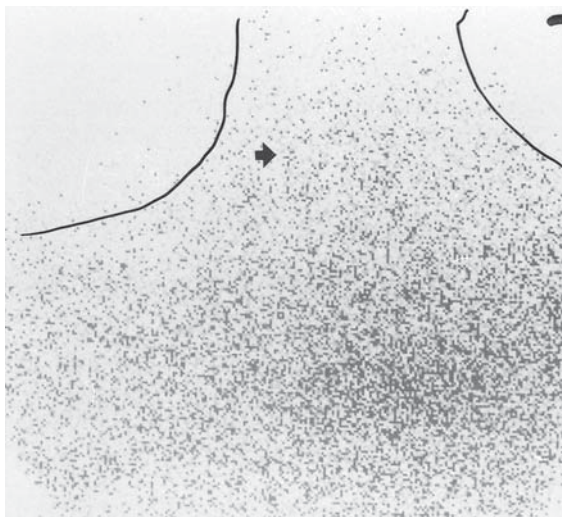


Fig. 4a. The thyroid gland was not visualized in the thyroid lodge (arrow) in a six-month-old boy using Tc-99m pertechnetate.

Case 5**Dyshormonogenesis**

An 18-month-old male with growth and motor retardation was screened for congenital hypothyroidism. The patient had an elder brother on thyroid hormone replacement

therapy due to organification defect. He had elevated TSH level so a thyroid scintigraphy with Tc-99m pertechnetate was performed to evaluate the thyroid gland. The scan revealed an enlarged gland with normal localization (Fig. 5).

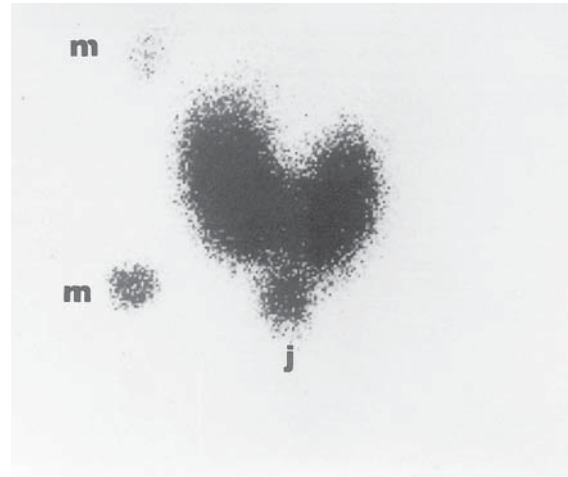


Fig. 5. An 18-month-old boy presented with enlarged goiter and increased uptake of 99m-Tc pertechnetate, secondary to TSH stimulation. The gland was enlarged [markers (M) on the lateral side of the gland measure 5 cm] and just above the sternal notch (J).

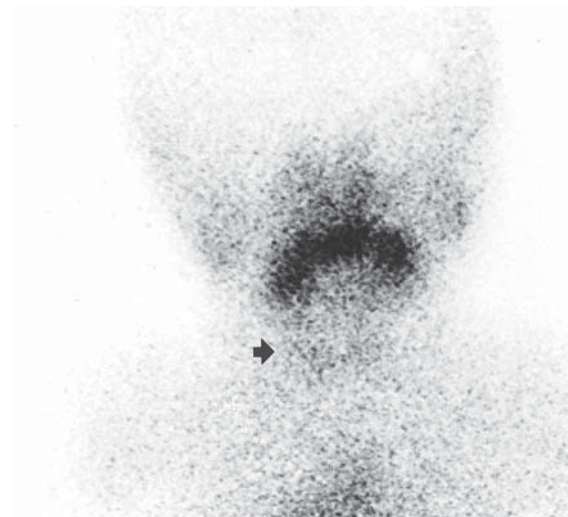


Fig. 4b. Repeated thyroid scintigraphy two months later showed faint radioactivity uptake in the thyroid gland (arrow).

Discussion

Permanent congenital hypothyroidism is reported with an incidence of 1 in 4,500³. The most common cause of congenital hypothyroidism is iodine deficiency. Thyroid dysgenesis accounts for the remainder of

the cases including agenesis, ectopia and hypoplasia. Thyroid agenesis is seen in one-third of dysgenesis cases⁴. The evaluation of these patients starts with thyroid function tests and thyroid/neck US. US is a noninvasive test when evaluating patients, but its main disadvantages are that it is operator dependent, it does not give functional information and the probe size is relatively large for the tiny newborns. Thyroid scintigraphy using Tc-99m pertechnetate is a relatively noninvasive technique giving minimal radiation dose to the patient (0.13 rad/mCi)⁵ that can be used successfully in the differential diagnosis of neonatal hypothyroidism. Patients can be imaged without sedation and images of the neck as well as mediastinum can be obtained when evaluating for ectopic localization. Although similar diagnostic accuracy has been reported for both US and scintigraphy for thyroid glands with normal localization, scintigraphic evaluation of the patients is essential when US fails to localize the ectopic tissue⁴.

Ectopic thyroid gland localization may be lingual or sublingual, in the remnants of the thyroglossal duct, the mediastinum and even in the pericardium. The base of the tongue just behind the foramen cecum⁶ is the most common localization. These glands do not function properly, and enlargement is common under TSH stimulation. Such patients frequently have hypothyroidism with or without obstructive symptoms, as seen in the second case⁷. Using markers during thyroid scintigraphy with Tc-99m pertechnetate at the mandibular angle and chin aids in differentiation of the proper localization (Fig. 2b)^{2,8}.

Cysts can be seen along the route of thyroid descent, in the remnants of the thyroglossal duct, which normally atrophies during embryonic development. Functional follicular thyroid cells are found in these remnants⁷. Although an ectopic thyroglossal thyroid gland may present with hypothyroidism, this accessory thyroid tissue can be asymptomatic and stay silent for decades⁷. Most of the cases are discovered incidentally as described in Case 3. Presence of functional remnants of thyroid tissue is a rare occasion, therefore metastatic thyroid adenocarcinoma should be kept in mind when such functional focus is detected on thyroid scintigraphy. Moreover, these remnants contain follicular thyroid cells, which may

develop into adenocarcinoma⁷. Case 3 had both multinodularity of the thyroid gland and functional focus on the neck. Although the thyroglossal cyst was palpated and described on US, she was at risk of thyroid adenocarcinoma and therefore underwent thyroidectomy.

The most important problem in neonatal hypothyroidism is determining the permanence of the condition. The diagnostic approach should include thyroid function tests and antibody screening tests as well as imaging procedures. Transient hypothyroidism may present with non-visualization of the thyroid gland on scintigraphy, and maternal antibodies are the cause in 5%³. Pathogenesis includes suppression of iodine uptake, which is inhibited by blocking maternal antibodies. Usually US examination reveals normal or small thyroid gland. This condition may last for 3-6 months, gradually returning to normal due to antibody catabolism, as seen in Case 4⁹.

Infants with the presentation of goiter and TSH elevation due to hereditary metabolic disorders are classified as dyshormonogenesis and this diagnosis accounts for 10-20% of the congenital hypothyroid cases⁴. There are various causes of dyshormonogenesis, such as defects in thyroid hormone release, iodotyrosine coupling, oxidative iodination and iodide trapping³. Moreover, genetic defect of TSH receptors results in unresponsiveness to TSH^{8,10}. The most common reason is the iodine organification defect. Specific genetic mutations of such disorders have been identified⁴. One well-known type of dyshormonogenesis is an autosomal recessive disorder, Pendred's syndrome, characterized by goiter, defective oxidative iodination and deafness¹. In this syndrome, a mutation is present in the pendrin-induced transport system. Goiter is found in 50% of the patients and the diagnosis can be made by perchlorate discharge test, showing uptake of iodine-123 and back diffusion of inorganic iodine¹. As Sfakianakis et al.⁹ noted, the diagnosis of dyshormonogenesis can be made by pertechnetate thyroid scintigraphy. Such patients have decreased T3 and T4 levels, which stimulates TSH secretion by a negative feedback mechanism. Elevated TSH hormone levels stimulate the thyroid gland, resulting in enlarged thyroid gland, as seen in Case 5⁹. The positive history of presence of an elder brother with hypothyroidism also supports this diagnosis.

In conclusion, evaluation of neonatal hypothyroidism is important in order to plan proper therapy. As delayed therapy may result in retardation of mental and motor development, a further diagnostic procedure such as thyroid scintigraphy is essential.

The authors suggest that thyroid scintigraphy with Tc-99m pertechnetate provides important clues in the identification of the cause of hypothyroidism and in follow-up in the pediatric population.

REFERENCES

1. Henkin RE, Boles MH, Karesh SM, et al. Nuclear Medicine. St Louis, Missouri: Mosby Yearbook; 1996: 850-855.
2. Sandler MP, Patton JA, Portain CL. Thyroid and Parathyroid Imaging. Connecticut: Appleton Century Crafts; 1986: 149-178.
3. Braverman LE, Utiger RD. Werner and Ingbar's The Thyroid (7th ed). Philadelphia: Lippincott-Raven Publishers; 1996: 984-999.
4. Meller J, Becker E. The continuing importance of thyroid scintigraphy in the era of high-resolution ultrasonography. *Eur J Nucl Med* 2002; 29 (Suppl): S425-430.
5. Sandler MP, Patton JA, Cross M, et al. Endocrine Imaging. Norwalk: Appleton and Lange; 1992: 197.
6. Moore KL, Persaud TV. The Developing Human (5th ed). Philadelphia: WB Saunders Company; 1993: 200-202.
7. Sandler MP, Coleman RE, Patton JA, Wackers FJ, Gottschalk A. Diagnostic Nuclear Medicine (4th ed). Philadelphia: Lippincott & Wilkins; 2003: 648-649.
8. Kiratlı PÖ, Gordon I, Nagaraj N. Neonatal hypothyroid disease-absent salivary gland evident on Tc-99m pertechnetate scan. *Clin Nucl Med* 2001 26: 310-313.
9. Sfakianakis GN, Ezuddin SH, Sanchez JE, Eidson M, Cleveland W. Pertechnetate scintigraphy in primary congenital hypothyroidism. *J Nucl Med* 1999; 40: 799-804.
10. Panoutsopoulos G, Mengreli C, Ilias I, Batsakis C, Christakopoulou I. Scintigraphic evaluation of primary congenital hypothyroidism: results of the Greek screening program. *Eur J Nucl Med* 2001; 28: 529-533.