

## Back to the basics: hemorrhage after vaccination: a case report

A. Bülent Cengiz, Güler Kanra, Ateş Kara, Metehan Özen, Mesut Konu  
İlkay Erdoğan, Mualla Çetin

Department of Pediatrics, Hacettepe University Faculty of Medicine, Ankara, Turkey

**SUMMARY:** Cengiz AB, Kanra G, Kara A, Özen M, Konu M, Erdoğan İ, Çetin M. Back to the basics: hemorrhage after vaccination: a case report. Turk J Pediatr 2004; 46: 259-261.

A 50-day-old girl with swelling and ecchymosis of right hand dorsum after DTP vaccination on ipsilateral deltoid area was referred to the pediatric infectious disease outpatient unit with a presumed diagnosis of gangrenous cellulites. Physical examination and laboratory evaluation revealed intramuscular bleeding as a result of vitamin K deficiency. We would like to emphasize the importance of both vitamin K prophylaxis in the newborn to prevent hemorrhagic disease of the newborn and of the education of persons administering vaccines about this very basic aspect of pediatrics for early recognition.

**Key words:** vaccination side effect, vitamin K deficiency, infant, bleeding, hemorrhagic disease of the newborn.

Immunization is part of the daily practice of every physician in charge of infants and children. This task is facilitated by specific recommendations on vaccine types, doses and schedules provided by public health authorities for adequate use of vaccine products. These practices can be readily used for all healthy children. However, medical problems can be seen after vaccination in some children.

Here, we present a 50-day-old girl with swelling and ecchymosis of right hand dorsum after DTP vaccination who was referred to the pediatric infectious disease outpatient unit with a presumed diagnosis of gangrenous cellulitis. She was diagnosed as having intramuscular and intracranial hemorrhages as a result of vitamin K deficiency. In the case of hemorrhage after injection, even as with vaccination, hemorrhagic disease of the newborn (HDN), one of the basic concepts of pediatric practice, must be considered before any complex and costly investigation. We would like to emphasize the importance of the education of persons administering vaccines about this very basic aspect of pediatrics.

### Case Report

A 50-day-old female infant born in a local hospital at full term presented with swelling and ecchymosis of the right hand dorsum. Her

delivery was uneventful and her birth weight was 3500 g. The infant was previously healthy and exclusively breastfed. The history of vitamin K administration at birth was unknown. There was reportedly no umbilical bleeding.

Five days previously, she had received BCG, DTP and OPV vaccination. On the same night, she developed fever and later experienced generalized convulsion for 30 seconds. She was not further investigated by the local physicians since vaccination had been cited for the convulsion. Two days after vaccination she developed profound bruise and edema on the right hand. She was seen by a physician and followed up with a diagnosis of localized trauma without any intervention. On the follow-up, since her edema and ecchymosis were worsening, she was referred to Hacettepe University with a presumed diagnosis of gangrenous cellulitis (Figs. 1 and 2). There was no documented bleeding diathesis history in the family.

Laboratory investigations revealed coagulopathy as follows: international normalized ratio (INR) (normal range, 0.75-1.50), and activated partial thromboplastin time (aPTT) (normal range, 29-47 s) were over the range of laboratory limit (laboratory upper limits 10 and 180s, respectively). Factor XIII and fibrinogen levels were within normal limits. The patient also

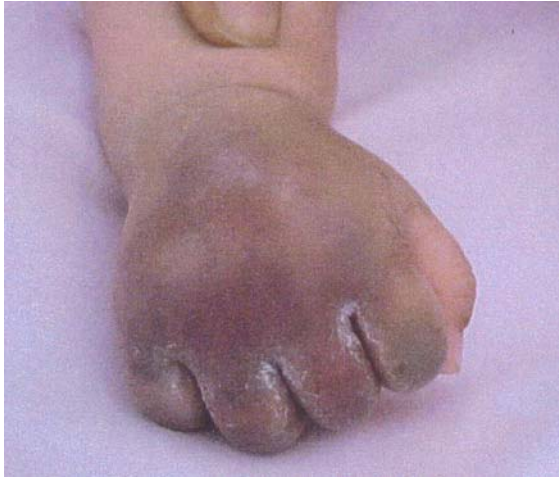

Fig. 1. Right hand of the patient.

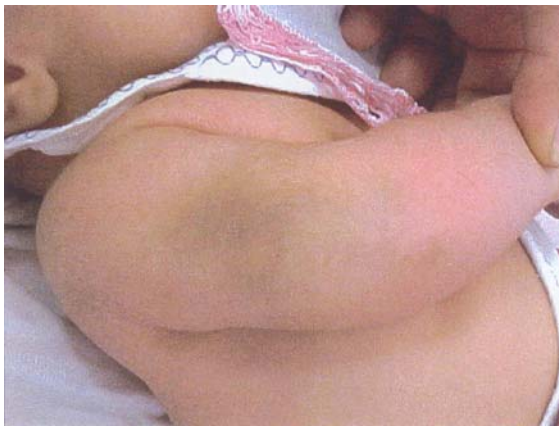

Fig. 2. Deltoid area of the patient.

suffered anemia; hemoglobin concentration of 7.7 g/dl, hematocrit 22%. The platelet number checked for hemorrhage etiology was normal 415,000/mm<sup>3</sup>. Alanine aminotransferase (ALT) 19 U/L, aspartate aminotransferase (AST) 32 U/L and total direct bilirubin levels were within normal limits (1.24 mg/dl and 0.24 mg/dl, respectively). Cranial computed tomography (CT) revealed multiple intracerebral hemorrhages (Fig. 3). We suspected bleeding as a result of vitamin K deficiency. She was hospitalized, received 3 mg vitamin K intravenously and was transfused with a packed erythrocyte suspension and fresh frozen plasma. After this therapeutic approach, control laboratory investigation revealed INR and aPTT within normal limits, 1.19 and 31.7 seconds,

respectively, and no convulsion was seen during the follow-up period. It is recommended that primary immunization be completed under the supervision of immunization experts.

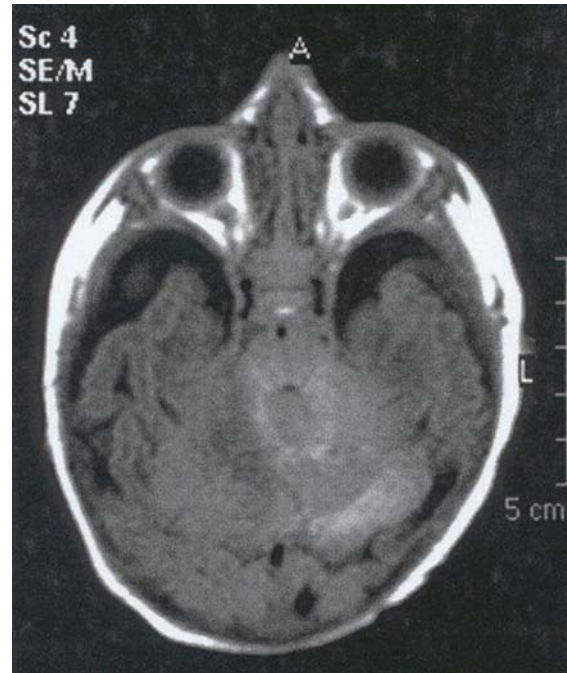


Fig. 3. Intra-cerebral hemorrhage in the computed tomography.

## Discussion

Levels of vitamin K-dependent coagulation factors (Factor II, VII, IX and X) are lower in neonates than in adults and thus vitamin K deficiency can cause bleeding in an infant in the first weeks of life<sup>1-4</sup>. This condition is known as hemorrhagic disease of the newborn<sup>3</sup>. HDN is divided into three categories: early, classic and late HDN<sup>2,3</sup>. Early HDN occurs in the first 24 hours of life and classic HDN from one to seven days. In late form (from second week to six months) intracranial, cutaneous, and gastrointestinal bleeding are the commonest manifestations<sup>1,3</sup>. The most frequent presentation of late HDN is encountered in exclusively breast-fed infants who did not receive vitamin K at birth<sup>1,2,5</sup>. Rarely late HDN may be the presenting feature of an underlying disease (e.g. cystic fibrosis,  $\alpha$ 1-antitrypsin deficiency or biliary atresia)<sup>2,5</sup>. The incidence of late HDN has been reported to vary from 4.4 to 10.5/100,000 births<sup>6</sup>.

This patient had normal platelet count, fibrinogen level, and liver function tests, and aPTT and INR normalized after administering 3 mg vitamin K. Therefore we concluded that the patient had vitamin K deficiency and in turn hemorrhage due to absence of coagulation factors. Lack of vitamin K prophylaxis at birth and exclusive breast-feeding were the main causes of the late HDN in this case. Although vitamin K prophylaxis, a single intramuscular injection of 1 mg at birth, is routinely administered in Turkey, we could not obtain any data in this patient's hospital records. In any case, it is known that late HDN rarely occurs in infants after intramuscular vitamin K prophylaxis at birth<sup>6-9</sup>.

Late HDN is particularly associated with intracranial hemorrhage<sup>5,10</sup>. The locations of the intracranial hemorrhage may be intracerebral, subarachnoid, subdural or intraventricular<sup>5,10</sup>. In this case, convulsion might have been the result of either intracranial hemorrhage or the pertussis component of DTP vaccine side effect. In our opinion, injection induced stress might result in the intracranial hemorrhage that caused the convulsion in this infant.

In view of the fact that our patient was examined by a physician just after development of localized bruise, we would like to emphasize the importance of vitamin K prophylaxis in the newborn to prevent HDN. In addition we wish to highlight the importance of educating persons administering vaccines, probably who are the first medical staff to see newborns, about intramuscular hemorrhages after injection, which could be an early sign of the

late HDN. We also emphasize that in any unexpected event after vaccination, before citing the vaccine as the cause, other possible underlying conditions must be investigated.

#### REFERENCES

1. Suzuki S, Iwata G, Sutor AH. Vitamin K deficiency during the perinatal and infantile period. *Semin Thromb Hemost* 2001; 27: 93-98.
2. Zipursky A. Prevention of vitamin K deficiency bleeding in newborns. *Br J Haematol* 1999; 104: 430-437.
3. Puckett RM, Offringa M. Prophylactic vitamin K for vitamin K deficiency bleeding in neonates. *Cochrane Database Syst Rev* 2000; 4: CD002776.
4. Autret-Leca E, Jonville-Bera AP. Vitamin K in neonates: how to administer, when and to whom. *Paediatr Drugs* 2001; 3: 1-8.
5. Bör Ö, Akgün N, Yakut A, Sarhuş F, Köse S. Late hemorrhagic disease of the newborn. *Pediatr Int* 2000; 42: 64-66.
6. von Kries R, Hanawa Y. Neonatal vitamin K prophylaxis: report of Scientific and Standardization Subcommittee on Perinatal Haemostasis. *Thromb Haemost* 1993; 69: 293-295.
7. Cornellison M, von Kries R, Loughnan P, Schubier G. Prevention of vitamin K deficiency bleeding: efficacy of different multiple oral dose schedules of vitamin K. *Eur J Pediatr* 1997; 156: 126-130.
8. Solves P, Altes A, Ginovart G, Demestre J, Fontcuberta J. Late hemorrhagic disease of the newborn as a cause of intracerebral bleeding. *Ann Hematol* 1997; 75: 65-66.
9. Latini G, Quartulli L, De Mitri B, Del Vecchio A, Vecchio C. Intracranial hemorrhage associated with vitamin K deficiency in a breastfed infant after intramuscular vitamin K prophylaxis at birth. Follow-up at 18 months. *Acta Paediatr* 2000; 89: 878-880.
10. Aydın N, Çıtak A, Çalışkan M, Karaböcüoğlu M, Baysal S, Özmen M. Vitamin K deficiency-late onset intracranial haemorrhage. *Eur J Paediatr Neurol* 1998; 2: 199-203.