

An uncommon cause of neonatal respiratory distress

Gabriel Dimitriou¹, Ageliki A. Karatza¹, Alexandra Mermiga¹, Ioannis Giannakopoulos¹, Markos Marangos², Stefanos P. Mantagos¹

¹Department of Pediatrics, Neonatal Intensive Care Unit, and ²Department of Internal Medicine, Infectious Diseases Section, University of Patras Medical School, Rio, Patras, Greece

SUMMARY: Dimitriou G, Karatza AA, Mermiga A, Giannakopoulos I, Marangos M, Mantagos SP. An uncommon cause of neonatal respiratory distress. *Turk J Pediatr* 2010; 52: 642-644.

We describe a term infant without any features of congenital infection, who presented with respiratory distress at birth. Respiratory distress persisted despite change of antibiotics, and chest radiography showed bilateral diffuse patchy infiltrates. Congenital infections screening obtained on the 10th day of life was reported positive for syphilis. The infant was started on penicillin G and came off oxygen within five days. Although the presentation of congenital syphilis as pneumonitis in the absence of other clinical signs is unusual, in view of the re-emergence of the disease, syphilitic involvement of the lungs should be considered in any infant presenting with persistent diffuse lung disease of unknown etiology.

Key words: congenital syphilis, pneumonia alba, syphilitic pneumonitis, neonatal respiratory distress, syphilis screening.

In most of the third world, congenital syphilis (CS) remains a significant problem. Although its prevalence fell between 1990 and 2000, recent reports suggest a re-emergence of CS in several developed countries^{1,2}. Neonatal findings are sometimes subtle and clinical diagnosis is often difficult. Lung involvement in the absence of other clinical features is an uncommon presentation of the disease, and radiographic findings are non-specific. Early recognition of syphilitic pneumonitis on a chest radiograph would result in early appropriate treatment, thus limiting the transmission of this highly contagious disease to the Neonatal Intensive Care Unit and nursery patients and personnel³.

Case Report

An appropriate-for-gestational age male infant was born at 37 weeks of gestation to a 23-year-old healthy primigravida who received regular antenatal care. The mother was a housewife who was a refugee from Eastern Europe. First trimester screening was negative for congenital infections, but serologic testing for syphilis was not performed. The infant

was delivered by spontaneous vaginal delivery and was transferred to the Neonatal Intensive Care Unit five hours after birth because of the emergence of respiratory distress. On admission, physical examination revealed grunting and a spontaneous respiratory rate of 80 breaths per minute. No features of congenital infection were present. Chest radiography showed a fine granular lung pattern compatible with respiratory distress syndrome. The infant was intubated and was supported initially with high frequency oscillatory ventilation. Two doses of exogenous natural surfactant were administered, ampicillin and an aminoglycoside were given, and the infant was extubated to headbox oxygen on day 3 of life.

Respiratory distress was persistent despite change of antibiotic therapy. Chest radiography showed bilateral streaky opacities, diffuse patchy infiltrates and consolidation of the right upper lobe (Fig. 1a). On day 8 of life, superficial desquamation was noted on both palms. Screening for congenital infections was obtained on day 10, and RPR (rapid plasma reagin) and VDRL (Venereal Disease Research Laboratory) were reported positive. *Treponema pallidum* hemagglutination (TPHA)

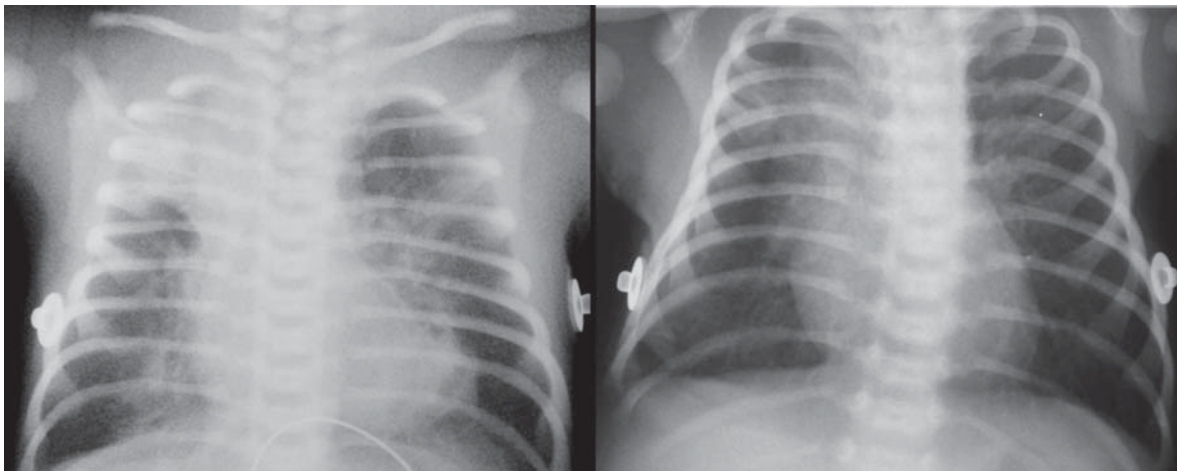


Fig. 1. (a) Chest radiography on the 5th day of life showing bilateral streaky opacities, diffuse patchy infiltrates and consolidation of the right upper lobe; (b) Repeat chest radiography on the 16th day of life revealing resolution of pulmonary infiltrates.

and FTA-IgM (fluorescent treponemal antibody-immunoglobulin M) were also positive, whereas cerebrospinal fluid examination was negative for treponemes (Table I). Ophthalmologic examination, long-bone radiographs, liver function tests, auditory function, echocardiography, and cranial and abdominal ultrasonography were within normal limits. Serologic testing of both mother and child was negative for human immunodeficiency virus. The infant was started on aqueous crystalline penicillin G and came off oxygen within five days. Repeat chest radiography revealed resolution of pulmonary infiltrates (Fig. 1b). The infant was followed at regular intervals and physical examination was unremarkable. RPR, VDRL and the FTA-IgM and FTA-IgG tests performed at 6 and 12 months of age were negative.

Discussion

Congenital syphilis (CS) is a rare disease; however, an increasing trend of positive antenatal syphilis serology has been noticed in women of childbearing age that may lead to unrecognized cases of CS⁴. CS is a totally preventable disease. The U.S. Preventive Services Task Force found convincing observational evidence that the screening of pregnant women decreases the proportion of infants with clinical manifestations of syphilis infection and recommended universal antenatal serologic testing for syphilis (Grade A recommendation)⁵.

The European Sexually Transmitted Diseases Guidelines Editorial Board also recommends that all pregnant women should be screened for syphilis at the first antenatal appointment⁶. Whether or not this should be repeated subsequently in pregnancy depends on the local epidemiology of syphilis within the population being screened⁶. The American Academy of Pediatrics and the American College of Obstetricians and Gynecologists state that all pregnant women should be screened for syphilis with serologic testing at the first prenatal visit, after exposure to an infected partner, and at the time of delivery⁵. They recommend that pregnant women who are considered at high risk for acquiring syphilis should also be tested at the beginning of the third trimester⁵. CS occurs in infants born to mothers who live under conditions of extreme poverty, are recreational drug users or have limited access to health care facilities. Immigration is rapidly emerging as a risk factor of heterosexual syphilis, and indeed, a recent outbreak of CS has been reported in Europe, where the immigration source countries are from Eastern Europe⁷. Therefore, the need for routine antenatal screening for syphilis for European countries, including Greece, should be emphasized.

Despite recently published guidelines⁶, syphilis screening during pregnancy remains the exception rather than the norm in several settings⁸. In the case presented here, the

Table I. Serology Performed on Both Mother and Infant on the 10th Day of Life

Serology	Mother	Infant
RPR	1/64	1/16
VDRL	1/512	1/256
TPHA	1/40	1/160
FTA-IgM	1/50	1/200
Cerebrospinal fluid	N/A	(-)

RPR: Rapid plasma reagin. VDRL: Venereal Disease Research Laboratory. TPHA: Treponema pallidum hemagglutination. FTA-IgM: Fluorescent treponemal antibody immunoglobulin M. N/A: Not applicable.

mother was not offered serologic testing for the disease at her first antenatal appointment or later during her current pregnancy, although she had a high-risk social background for syphilis infection.

The most common clinical features of CS are hepatosplenomegaly, rash, anemia, jaundice, metaphyseal dystrophy, periostitis, cerebrospinal fluid changes, and snuffles⁹. Our patient did not demonstrate any of the above. Respiratory distress is an infrequent clinical feature of CS and has been described as “pneumonia alba” based on pathology findings¹⁰. The radiographic appearance of syphilitic pneumonitis is nonspecific. A recognizable radiological pattern compatible with alveolar and interstitial changes, with diffuse coarse nodular changes with band-like opacities radiating from the hilar area, has been reported⁹. A similar radiographic pattern was observed in our case. The persistence of respiratory findings despite the use of broad spectrum antibiotics, the absence of any infectious agent, and the resolution of both clinical symptoms and radiographic abnormalities after the serologic diagnosis of CS and the initiation of penicillin therapy were suggestive of syphilitic pneumonitis. Only half of the affected infants will be born with recognizable stigmata of CS³. Therefore, the presence of the radiological pattern described here in an infant with respiratory distress should lead to the addition of CS in the differential diagnosis.

The current recommended treatment regimen is aqueous crystalline penicillin G, 50,000 units per kilogram every 8 or 12 hours intravenously for at least 10 days. Treated seropositive infants should be followed up at 3, 6, and 12 months of age. Nontreponemal antibody titers should disappear at 6 months of age following successful treatment.

In conclusion, although the presentation of CS as pneumonitis in the absence of other clinical signs is unusual, in view of the re-emergence of the disease, syphilitic involvement of the lungs should be considered in any infant presenting with persistent diffuse lung disease of unknown etiology.

REFERENCES

- Centers for Disease Control and Prevention (CDC). Primary and secondary syphilis-United States, 2003-2004. *MMWR Morb Mortal Wkly Rep* 2006; 55: 269-273.
- Simms I, Fenton KA, Ashton M, et al. The re-emergence of syphilis in the United Kingdom: the new epidemic phases. *Sex Transm Dis* 2005; 32: 220-226.
- Chakraborty R, Luck S. Syphilis is on the increase: the implications for child health. *Arch Dis Child* 2008; 93: 105-109.
- Walker GJ, Walker DG. Congenital syphilis: a continuing but neglected problem. *Semin Fetal Neonatal Med* 2007; 12: 198-206.
- U.S. Preventive Services Task Force. Screening for syphilis infection in pregnancy: U.S. Preventive Services Task Force reaffirmation recommendation statement. *Ann Intern Med* 2009; 150: 705-709.
- French P, Gomberg M, Janier M, Schmidt B, van Voorst Vader P, Young H. IUSTI: 2008 European Guidelines on the Management of Syphilis. *Int J STD AIDS* 2009; 20: 300-309.
- Zenilman JM. Congenital syphilis in immigrants - are politics and nativism driving us in reverse? *Sex Transm Dis* 2008; 35: 344-345.
- Hawkes S. Eliminating congenital syphilis - if not now then when? *Sex Transm Dis* 2009; 36: 721-723.
- Pieper CH, van Gelderen WF, Smith J, Kirsten GF, Möhrcken S, Gie RP. Chest radiographs of neonates with respiratory failure caused by congenital syphilis. *Pediatr Radiol* 1995; 25: 198-200.
- Edell DS, Davidson JJ, Mulvihill DM, Majure M. A common presentation of an uncommon cause of neonatal respiratory distress: pneumonia alba. *Pediatr Pulmonol* 1993; 15: 376-379.