

ST-segment elevation following lightning strike: case report and review of the literature

Alper Akın¹, Meki Bilici¹, Fikri Demir¹, Ayfer Gözü-Pirinççioğlu², Ahmet Yıldırım³

Divisions of ¹Pediatric Cardiology and ²Pediatric Intensive Care, ³Department of Pediatrics, Dicle University Faculty of Medicine, Diyarbakır, Turkey. E-mail: alperakin1@hotmail.com

Received: 17 July 2014, Revised: 30 December 2014, Accepted: 16 January 2015

SUMMARY: Akın A, Bilici M, Demir F, Gözü-Pirinççioğlu A, Yıldırım A. ST-segment elevation following lightning strike: case report and review of the literature. *Turk J Pediatr* 2015; 57: 186-188.

Lightning strikes may cause injury to the heart, ranging from slight electrocardiographic changes to fatal damage. As heart injury is the most important cause of mortality in these patients, cardiac monitoring is crucial. Even though various ECG changes have been reported, published data on pathologic ST-segment changes is scarce. Herein, we present a seven-year-old patient with ST-segment elevation following a lightning strike. There is not sufficient data regarding lightning-related myocardial ischemia. However, because of the similar effects of lightning strikes and high-voltage electric shocks, we believe myocardial injury related to lightning may be managed in the same manner as is cardiac involvement associated with electric shock.

Key words: ST-segment elevation, lightning strike, child.

Lightning strike is characterized by high mortality and long-term morbidity. In contrast to electric shocks in household and industrial situations caused by alternative current (AC), lightning strike exposes the victim to direct current (DC). The energy carried usually amounts to between 100 million and 1 billion V, and the direct current to 30,000-50,000 A, values very much higher than are seen in the case of AC¹. Even though various ECG changes have been reported after lightning strikes, published data on pathologic ST-segment changes is scarce. Herein, we present a seven-year-old patient with ST-segment elevation following a lightning strike.

Case Report

A seven-year-old girl underwent resuscitation upon experiencing cardiorespiratory arrest due to a lightning strike and was transferred to our hospital intubated and with respiratory support. Her general condition was poor, with a Glasgow Coma Scale (GCS) of 3; there was a left supra-scapular 2nd-3rd degree burn. The patient was mechanically ventilated. Her apical heart rate was 112/min; heart sounds were regular, and her arterial blood pressure was 105/75 mmHg. Blood gas analysis showed

metabolic acidosis (pH 7.23, HCO₃ 18 mmol/L, pCO₂ 47 mmHg). Troponin I was 55.47 ng/ml (normal range 0-0.04) and CK-MB 70.1 ng/ml (normal 0.6-6.63 ng/ml). Other blood values were as follows: WBC 15,600/mm³, hemoglobin 10.6 g/dl, platelets 264x10³/ml, urea 70 mg/dl, creatinine 1.01 mg/dl, uric acid 4.4 mg/dl, sodium 161 mg/dl, potassium 5.1 mg/dl, AST 161 U/L, LDH 1304 U/L. An ST-segment elevation unaccompanied by a pathologic Q-wave was seen on surface ECG, more pronouncedly on derivations DII and DIII (Fig. 1). Transthoracic echocardiography (TTE) showed normal systolic function, without hypokinetic or akinetic segments. Cardiac enzymes troponin I and CK-MB gradually subsided, reaching 11.7 and 9.6 ng/ml, respectively, by the fifth day after admission. Daily follow-up of ECG and TTE did not show any changes. The patient remained unconscious and supported by mechanical ventilation until the fifth day after admission, when she was lost to brain death.

Discussion

When an individual is struck by lightning, cardiovascular complications may develop through direct thermal damage, catecholamine-

mediated effects, coronary artery spasm, ischemia secondary to arrhythmia and diffuse vascular injury. Direct exposure to lightning may affect myocardial transmembrane potentials, leading to temporary or long-term dysrhythmia, or tetanic inotropic stimulation that may cause ventricular asystole. Even though the results of cardiac injury may be reversible, respiratory arrest as a result of damage to the respiratory center in the brainstem may occur. Hypoxia/anoxia may then also contribute to myocardial depression^{1,2}. The prognosis of patients who experience cardiopulmonary arrest and/or brain damage from hypoxia is relatively poor³. Our patient presented with features indicating a poor prognosis, including the occurrence of cardiopulmonary arrest, loss of consciousness indicating probable hypoxic brain injury and a low GCS.

Cardiac rhythm may be affected by direct action from electrical or mechanical trauma, or by indirect action through autonomic stimulation and excessive release of catecholamines. Lightning strike is believed to cause asystole by administering an electric shock similar to that of defibrillation. In the absence of other organ pathology that may worsen the heart injury, the human organism reverts rapidly to sinus rhythm, as it does in a defibrillation².

Acute myocardial infarction (MI) or ischemia due to lightning strike is rare^{4,5}. Myocardial ischemia and infarction have been identified in the absence of any thromboembolic coronary occlusion or vasoconstriction⁶. Infarction may develop as a result of direct tissue damage or lightning-induced vasospasm². ST segment and T-wave abnormalities have been reported to generally recover spontaneously; this may be a result of autonomous instability rather than myocardial lesions⁷. ST-segment elevation is mostly seen in the inferior leads, as in our patient. This is due to the relative proximity of the right coronary artery to the chest surface⁸. Çelebi et al.⁸ observed a biphasic T-wave and an ST-segment elevation >1 mm in the inferior leads in a 25-year-old patient who had been exposed to electric current; they reported this as a MI finding. This patient was given supportive (beta-blocker and ACE inhibitor) therapy; minimal ECG changes were reported at the end of one year of follow-up.

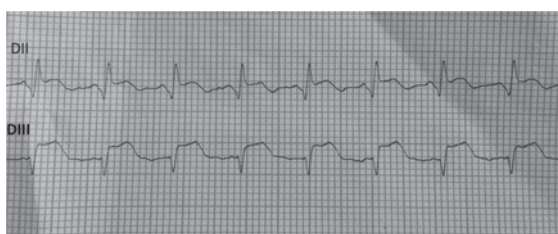


Fig. 1. An ST-segment elevation was seen on surface ECG, on derivations DII and DIII.

There is no data on the use of coronary angiography for diagnostic purposes in the presence of ischemia of infarction due to lightning. Considering the similarity of the pathogenesis, the consensus following a study of patients who developed similar ECG findings after electrocution is that medical treatment is indicated⁸⁻¹⁰. ST-segment elevation and a Q-wave in the anterior leads were seen in a 16-year-old patient who had experienced an electric shock, while the coronary arteriography was unremarkable⁹. Another patient, aged 19, showed an ST-segment elevation in the anterior leads; this patient died. The coronary arteries were normal on post-mortem examination¹⁰. The myocardial damage is therefore believed to derive from coronary vasospasm rather than coronary thrombosis^{9,10}. No coronary angiography was performed in our patient because of her poor general condition. Taking into consideration the patient's clinical status and the facts of the cases published in the available literature, we believe that the ECG findings were probably due to coronary vasospasm.

To conclude, even though published information on the mechanisms of cardiac damage related to lightning strike is insufficient, these patients are probably subject to conditions similar to those of persons exposed to a high-voltage electrical current. In the presence of findings suggestive of myocardial damage, the decision should be made considering data from advanced diagnostics, existing publications and concomitant conditions. We believe that invasive procedures such as coronary angiography may be unnecessary, considering the fact that coronary vasospasm is most probable, and that patients may be best managed by medical treatment and follow-up.

REFERENCES

1. Ritenour AE, Morton MJ, McManus JG, Barillo DJ, Cancio LC. Lightning injury: a review. *Burns* 2008; 34: 585-594.
2. McIntyre WF, Simpson CS, Redfearn DP, Abdollah H, Baranchuk A. The lightning heart: A case report and brief review of the cardiovascular complications of lightning injury. *Indian Pacing Electrophysiol J* 2010; 10: 429-434.
3. Cooper MA. Emergent care of lightning and electrical injuries. *Semin Neurol* 1995; 15: 268-278.
4. Zack F, Hammer U, Klett I, Wegener R. Myocardial injury due to lightning. *Int J Legal Med* 1997; 110: 326-328.
5. Jensen PJ, Thomsen PE, Bagger JP, Nørgaard A, Baandrup U. Electrical injury causing ventricular arrhythmias. *Br Heart J* 1987; 57: 279-283.
6. Saglam H, Yavuz Y, Yurumez Y, Ozkececi G, Kilit C. A case of acute myocardial infarction due to indirect lightning strike. *J Electrocardiol* 2007; 40: 527-530.
7. Ruiz Ruiz FJ, Ruiz Laiglesia FJ, Lobo Escolar A, Hualde Enguita AM, Torrubia Pérez CB, Calvo Begueria E. [Cardiac injury after indirect lightning strike]. [Article in Spanish] *Rev Esp Cardiol* 2002; 55: 768-770.
8. Celebi A, Gulel O, Cicekcioglu H, Gokaslan S, Kututcularoglu G, Ulusoy V. Myocardial infarction after an electric shock: a rare complication. *Cardiol J* 2009; 16: 362-364.
9. Walton AS, Harper RW, Coggins GL. Myocardial infarction after electrocution. *Med J Aust* 1988; 148: 365-367.
10. Xenopoulos N, Movahed A, Hudson P, Reeves WC. Myocardial injury in electrocution. *Am Heart J* 1991; 122: 1481-1484.