

Acute focal bacterial nephritis developed in a healthy child

Demet Alaygut, Meral Bayram, Alper Soylu, Mehmet Türkmen, Salih Kavukçu

Department of Pediatric Nephrology, Dokuz Eylül University Faculty of Medicine, İzmir. E-mail: demetalaygut@yahoo.com

SUMMARY: Alaygut D, Bayram M, Soylu A, Türkmen M, Kavukçu S. Acute focal bacterial nephritis developed in a healthy child. Turk J Pediatr 2013; 55: 226-228.

Acute focal bacterial nephritis (AFBN) is a rare cause of interstitial bacterial nephritis. Ultrasound identifies AFBN as a hypoechogenic and hypoperfused parenchymal lesion, which requires its differentiation from renal abscess and tumor. Hematogenous spread or ascending infection arising from the lower urinary tract is thought to be involved in the pathogenesis of AFBN. Herein, a six-year-old healthy male patient, diagnosed using ultrasound and computerized tomography (CT) and treated with intravenous antibiotics, is presented. As a result, AFBN can be seen in healthy children without any history of reflux or urinary tract infection, and differentiation from renal abscess is important.

Key words: acute focal bacterial nephritis, renal abscess, healthy child, intravenous antibiotics.

Acute focal bacterial nephritis (AFBN) is an inflammatory mass created by localized bacterial infection without renal abscess formation. It is an intermediary entity between pyelonephritis and intrarenal abscess¹. In many cases, a concomitant malformative uropathy is present². A six-year-old, healthy male patient without any concomitant urologic anomaly is presented; he was diagnosed as AFBN and improved with intravenous (i.v.) antibiotherapy.

Case Report

A six-year-old male patient presented with complaints of fever, fatigue, abdominal pain, vomiting, and flank pain starting five days before. It was learned that he had been treated with i.v. cefuroxime for four days with the diagnosis of urinary tract infection and that abdominopelvic ultrasonography (USG) had detected findings consistent with pyelonephritis. His medical history was isoniazid prophylaxis for eight months because of detection of pulmonary tuberculosis in his family and recurrent episodes of otitis. His parents were non-consanguineous.

On physical examination, his body weight and height were within 50-75th percentiles; he had fever (38.5°C) and tachycardia (120 bpm) and was normotensive. He had diffuse abdominal tenderness on the abdominal examination and

left costovertebral angle tenderness.

Laboratory analyses revealed: hemoglobin (Hb): 9.3 g/dl (11.5-12.5 g/dl), hematocrit: 28% (34-37%), white blood cells (WBC): 21,000/mm³ (5.0-14.5x10³ /mm³), platelets (Plt): 175,000/mm³ (150-400x 10³/mm³ (0-20)), blood urea nitrogen (BUN): 10 mg/dl (9-23 mg/dl), creatinine: 0.4 mg/dl (0.6-1.1 mg/dl), sodium (Na): 134 mmol/L (132-146 mmol/L), potassium (K): 4.4 mmol/L (3.5-4.5 mmol/L), chlorine (Cl): 107 mmol/L (99-109 mmol/L), calcium (Ca): 8.6 mg/dl (8.3-10.6 mg/dl), phosphorus (P): 3.8 mg/dl (2.4-5.1 mg/dl), aspartate aminotransferase (AST): 20 U/L (0-34 U/L), alanine aminotransferase (ALT): 18 U/L (10-49 U/L), total bilirubin: 0.35 mg/dl (0.3-1.2 mg/dl), direct bilirubin: 0.24 mg/dl (0-0.2 mg/dl), total protein: 5.2 g/L (5.7-8.2 g/L), albumin: 3 g/L (3.2-4.8 g/L), C-reactive protein (CRP): 246 mg/L (0-5 mg/L), urinalysis: density: 1015, pH: 6, nitrite: protein, glucose: (-), microscopic findings: 35 RBC/high-power field (hpf), 85 WBC/hpf and 2 WBC clusters. Immunoglobulins were normal. On USG, increase in the left renal dimensions and an iso-hypoechoic lesion with a heterogeneous internal structure, localized in the left midrenal region measuring nearly 4 cm in diameter were detected. Blood and urine samples were sent for culture antibiogram, and then empirically meropenem-amikacin combination therapy

was started. On abdominal computerized tomography (CT), diffuse infection in the left kidney, findings consistent with AFBN, atelectatic lesion and consolidation area in basal regions of both lungs, and bilateral pleural fluid collection not extending 1 cm were detected (Fig. 1). On urine culture, 10^5 cfu/ml ESBL (+) *Escherichia coli* grew. Because of persistence of clinical findings and high fever on the 7th day of the antibiotherapy, percutaneous drainage under USG guidance was performed. Histopathologic examination of the specimen was consistent with renal abscess. ESBL (+) *E. coli* grew in the culture of the abscess material. Polymerase chain reaction (PCR) examination for tuberculosis was negative. A PPD test was performed, which caused a dermal reaction of 11 mm in diameter and normal chest X-ray. In flow cytometric phagocyte suppression test, a 98.7% cellular viability was found. Because of persistent febrile state, amikacin was stopped on the 12th day, and cefoperazone-sulbactam was added to his treatment protocol. During the observation period, acute phase reactants regressed and the relevant test demonstrated negativity. Follow-up CT (Fig. 2) and repeated USG examinations displayed normalized renal dimensions bilaterally and regression of previous lesions. Meropenem therapy was continued for a total of six weeks, while cefoperazone-sulbactam antibiotherapy was maintained for four weeks. His voiding

cystoureterographic (VCUG) examination was unremarkable.

Discussion

Acute focal bacterial nephritis (AFBN) has been described as an inflammatory and undrainable mass localized in the upper urinary system. It is known as acute lobar nephronia³.

The presence of clinical manifestations such as high fever, flank pain and pyuria suggests the diagnosis of AFBN. However, small children might not express flank pain and present with nonspecific symptoms like vomiting, diarrhea, dehydration, and paraumbilical pain. Because of these nonspecific symptoms, diagnosis of AFBN might be overlooked. In one study, 25 patients with AFBN had been evaluated, and the authors reported that these patients had presented with complaints of meningitis (n=4), urinary tract infection (n=5), renal tumor (n=3), pneumonia (n=2), and appendicitis (n=1). Still, in the same publication, the authors indicated that only 10 patients, with a mean age of 8 years, could express flank pain. Before referrals, in 21 of 25 children, upper respiratory tract infection (n=5), pneumonia (n=3), tonsillitis (n=5), urinary tract infection (n=5), gastroenteritis (n=1), mandibular abscess (n=1), and serious dental caries (n=4) were detected⁴. Before his referral to the hospital, our patient had suffered from recurrent otitis media episodes.

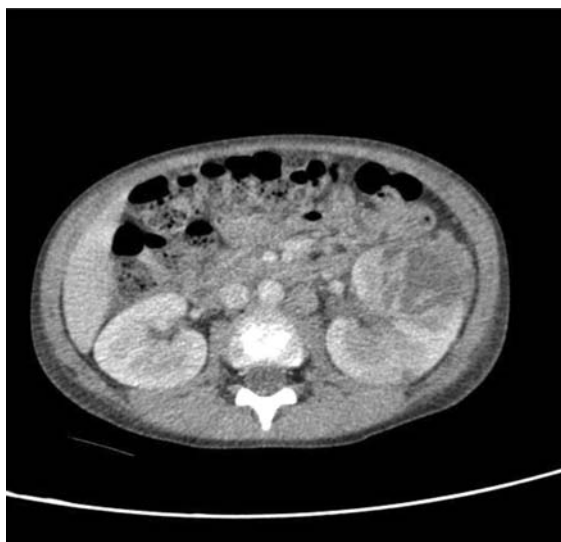

Fig. 1. Abdominal CT of the patient at the onset of the treatment. Lobar nephronia of the left kidney is apparent.

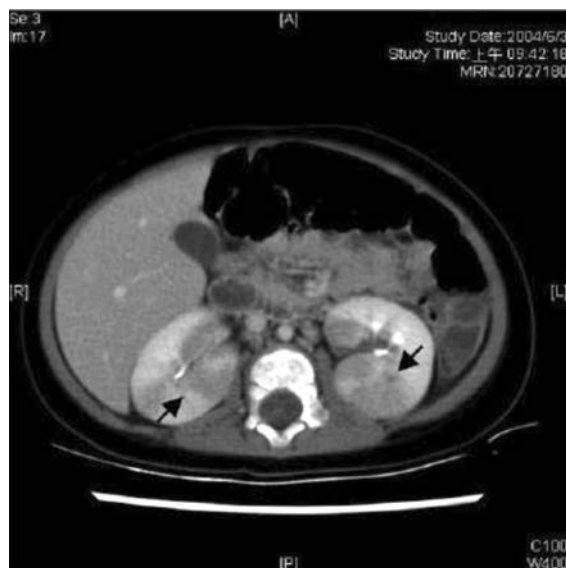


Fig. 2. Control CT obtained of the same patient under treatment demonstrates improving renal lesions.

For diagnostic purposes, USG is the first-line preferred imaging modality. Cheng et al.⁵ reported that renomegaly and image of a focal mass lesion are fairly useful diagnostic criteria for AFBN, with more than 95% sensitivity. However, in some cases, confirmation of the diagnosis by CT examination might be required. USG might demonstrate an iso-, hypo- or hyperechogenic lesion according to the stage of AFBN⁵. In our patient, the first USG revealed an iso-hypoechogenic lesion, and this finding was confirmed by CT examination. Hematogenous infection and ascending spread from the lower urinary tract are known to play a role in the pathogenesis of AFBN. For many children, ascending infection is more important. Though the most frequently seen infectious agent is *E. coli*, *Enterococcus faecalis* and *Pseudomonas aeruginosa* can be identified also^{4,6}. Many publications have implicated urologic abnormalities and especially vesicoureteral reflux^{1,7}. We could not detect any concomitant urologic anomaly in our patient.

Differentiation between AFBN and renal abscess is important. Indeed, these two different entities are important with respect to the treatment modality to be applied. It is mandatory to perform percutaneous drainage for the treatment of renal abscess. In AFBN, antibiotherapy is the essential treatment modality. However, in this case, intractable high fever persisting through the 7th day of the treatment necessitated application of percutaneous drainage under USG guidance to prevent conceivable progression to renal abscess formation.

Although for AFBN, i.v. treatment is recommended, clear-cut information about the optimal duration of the therapy is lacking^{5,8}. In a prospective study performed, the patients were divided into two groups. Group 1 received antibiotherapy for 2 weeks, and Group 2, for 3 weeks. In Group 1, 7 treatment failures, 1 persistent infection, and 6 infection recurrences were reportedly seen⁵. In our patient, 12 days after the onset of meropenem and amikacin treatment, amikacin was stopped because of persistent fever, and cefoperazone and sulbactam were started. Meropenem was continued for 6 weeks and cefoperazone-sulbactam for 4 weeks. Duration of treatment was determined based on serial USG monitoring of the lesion dimensions and the involved kidney, and the degree of

fever was controlled with clinical measures. Afterwards, oral trimethoprim at a daily dose of 1 mg/kg was started, and maintained during further investigations. In some cases, renal scar can develop despite antibiotherapy. Renal DMSA scanning performed at the termination of the treatment of this patient demonstrated normal right kidney and a lesion causing irregularities in posterior, midrenal lateral, and inferior contours of the left kidney, which could not be differentiated clearly between infection and renal scar. Follow-up scanning performed six months later revealed a renal cortical scar consistent with parenchymal scar, which caused contour irregularities of the left midrenal region. Optimal duration of antibiotherapy should be determined on the basis of individual cases and planned for at least three weeks⁵.

In conclusion, AFBN is not uncommon in previously healthy children with a first episode of febrile urinary tract infection, and should be considered as a differential diagnosis of renal parenchymal disease, especially antibiotic-resistant urinary tract infection, and in the evidence of focal pyelonephritis in USG and CT. Longer treatment periods with the appropriate antibiotics are recommended for the therapy of AFBN.

REFERENCES

1. Shimizu M, Katayama K, Kato E, et al. Evolution of acute focal bacterial nephritis in to a renal abscess. *Pediatr Nephrol* 2005; 20: 93-95.
2. Uehling DT, Hahnfeld LE, Scanlan KA. Urinary tract abnormalities in children with acute focal bacterial nephritis. *BJU Int* 2000; 85: 885-888.
3. Rosenstein AT, Glickman MG, Taylor KJ, et al. Acute focal bacterial nephritis (acute lobar nephronia). *Radiology* 1979; 132: 553-561.
4. Seidel T, Bröking EK, Kaczmarek S, et al. Acute focal bacterial nephritis in 25 children. *Pediatr Nephrol* 2007; 22: 1897-1901.
5. Cheng CH, Tsau YK, Lin TY. Effective duration of antimicrobial therapy for the treatment of acute lobar nephronia. *Pediatrics* 2006; 117: 84-89.
6. Dembry LM, Andriole VT. Renal and perirenal abscesses. *Infect Dis Clin North Am* 1997; 11: 663-680.
7. Cheng CH, Tsai MH, Su LH, et al. Renal abscess in children: a 10 year clinical and radiologic experience in a tertiary medical center. *Pediatr Infect Dis J* 2008; 27: 1025-1030.
8. Rathore MH, Barton LL, Luisiri A. Acute lobar nephronia: a review. *Pediatrics* 1991; 87: 728-734.